

The Utility of Covered Self Expanding Metal Stents in the Management of Complex Small Bowel Fistula

Khaled Demyati^{1,}; Wael Sadaqa²; Iyad Maqboul¹ & Alaa Rustom¹*

¹Department of Surgery, An-Najah National University Hospital, An-Najah National University, Nablus, Palestine. ²Department of Surgery, An-Najah National University Hospital, An-Najah National University, Nablus, Palestine

*Corresponding author: khaleddemiyati@najah.edu

Received: (28/9/2020), Accepted: (18/9/2021). DOI: <https://doi.org/10.59049/2790-0231.1066>

Abstract

Endoscopic procedures and stent technology innovations have significantly developed their usage in gastrointestinal illnesses. The use of stents in the GI tract has expanded to encompass a wide range of malignant and benign diseases and anatomical sites. However, whether covered self-expanding stents can help control postoperative small bowel leaks and fistulas is still not answered. Stent's utility in managing bowel leaks and fistulas is rarely reported, and no adequate evidence in the literature concerning its benefits and limitations. A 63-year-old patient had numerous surgeries for recurrent adhesive intestinal obstruction. The patient repeated laparotomies were complicated with multiple minor bowel injuries, high output complex enterocutaneous fistulas, extensive leaks, nutritional depletion, and major wound and skin breakdown. This report describes our approach for deploying covered self-expanding metallic stents (SEMS) in the small bowel to manage high output complex enterocutaneous fistulas in this patient. The clinical benefits and drawbacks of such clinical applications are described, and the problems and difficulties experienced.

Keywords: Covered Self Expanding Metal Stents, Stent, Complex, Small Bowel Fistula.

INTRODUCTION

Postoperative complications of enteral leaks and fistulas are significant morbidity and mortality. The management of these complications can be very challenging, especially in patients with multiple enteral fistulas with high output. Furthermore, these patients usually require prolonged hospitalization with wound care, nutritional support, sepsis control, and medical management before these fistulas can heal or surgical reconstruction can be performed. In such cases, the high output of succus, which can be acidic or alkali, rich in digestive juice, can further complicate patient care and cause severe skin excoriation and significant fluid electrolytes disturbance—recent advances in enteral stents design and composition introduced novel usage and indications. There is a wide array of endoscopic tools available to manage these complications to reduce mortality and morbidity and decrease the length of hospitalization. While a wide range of clinical applications of the metal stent has been heavily described and discussed in the literature [1, 2], their use in

managing small bowel high output fistulas has been rarely reported [3]. This report describes the utility of covered self-expanding metal stents in managing such patients. We express our technique in detail and discuss the problems faced and the targets achieved in a patient with an extreme case of multiple small bowel fistulas with a deplorable medical condition.

RESULTS

CASE REPORT

A 63-Year-old man had an old history of perforated duodenal ulcer at the age of 35 (1985), for which he required laparotomy with peritoneal lavage and Billroth II reconstruction. That surgery was complicated with recurrent adhesive small bowel obstruction for which he had repeated laparotomy and release of adhesions four times after that surgery (1986, 2000, 2003, and 2005). The patient required small bowel resection twice in the course of his illness. Recently, the patient was admitted again to a district hospital with adhesive bowel obstruction and a small bowel perforation. Surgery was performed at the same hospital

on February 9, 2018, with an emergency laparotomy. The perforated segment of the small bowel was resected, and primary anastomosis was performed. A few days later, the patient has noticed a small bowel leak with small bowel contents coming out of the laparotomy wound. CT scan was performed there and showed the small bowel leaking through a 3cm track to the through the laparotomy wound without intra-abdominal collections.

The patient was managed medically for two weeks; however, the patient deteriorated clinically and developed septicemia.

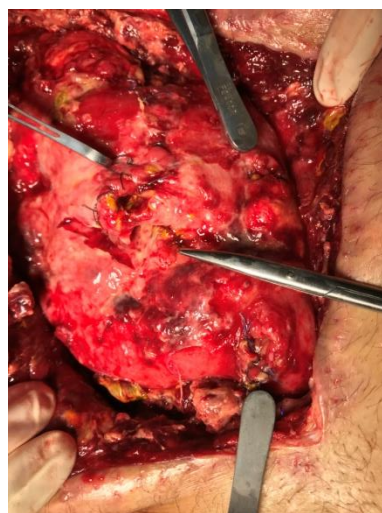
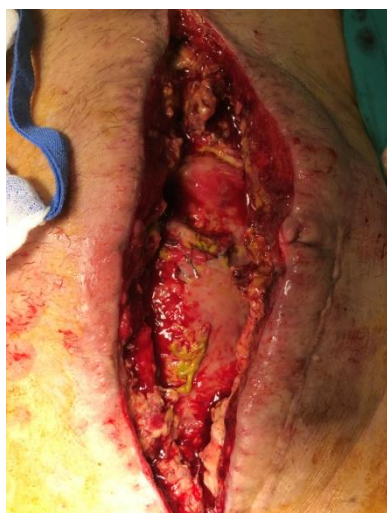
Figure (1): Major breakdown of the laparotomy wound. The small bowel loops seen in the wound are very inflamed and densely adherent with multiple fistula openings.

The patient was resuscitated; laparostomy wound care was initiated with sepsis control. Total parenteral nutrition started, and nonoperative therapy continued initially to resolve infection and inflammation and restore the peritoneal cavity. Wound exploration showed that the fistulas involved multiple bowel loops from different levels, including the proximal jejunum. In 3 months of medical management, most small bowel fistulas closed spontaneously, and the laparostomy wound partially closed. However, two large

proximal fistulas failed to recover and remained to leak large volumes of succus rich in bile and pancreatic juice. Drains, including suction drains and dressing techniques, could not control these fluids, causing severe skin excoriations and severe fluid-electrolyte disturbances (Figure 2). Furthermore, the patient remained in critical condition with severe malnutrition recurrent septicemia with several multidrug-resistant bacteria; most of these infections were catheter-related. The abdomen was still hard all over, indicating persistent inflammation.

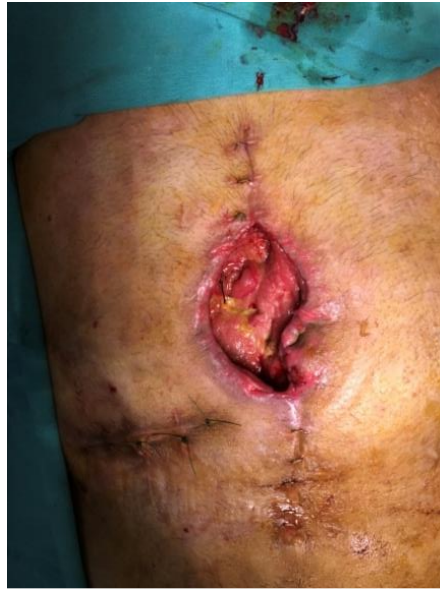

Figure (2): large proximal fistulas failed to recover with non-surgical therapy and remained to leak bile and pancreatic secretions rich fluid in large volumes.

At this point, we decided to insert coverer metal stents to bypass the remaining two large enterocutaneous fistulas (ECFs), aiming to help control soiling, relieve excoriation, reduce fluid loss, and resume oral feeding. We used two large diameters (23 mm) partially covered stents. The metal stents were controlled with multiple bands before the introducing catheter was removed to allow the stent from both sides from the fistula lumen. Half of the metal stent was deployed in one side of the fistulated

jejunum, and rubber bands controlled the rest to prevent it from expansion while being removed from the introduction set. This stent part was introduced manually to the other side of the fistulated jejunum. We released the rubber bands after inserting the rest of the stent in its planned position. Both stents were deployed successfully, and their position was maintained by tagging it to the skin by prolene sutures. This tagging was performed to prevent stents migration (Figure 3).

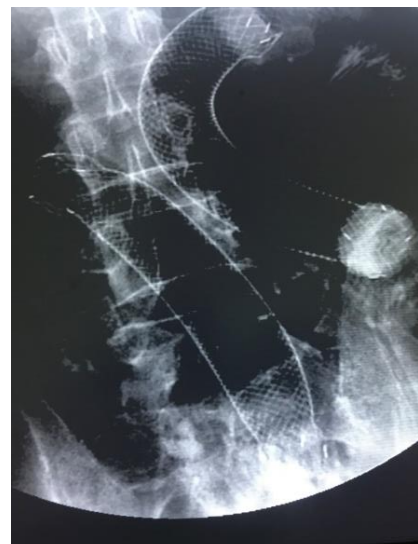
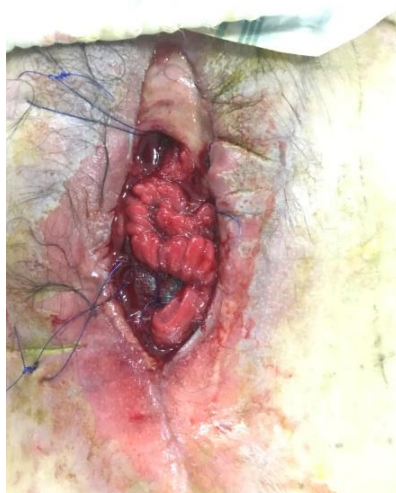

Figure (3): a) Two metal stents were deployed successfully, and their position was maintained by tagging it to the skin by prolene sutures to prevent stents migration. b) Fluoroscopic image showing the two metal stents in position after the successful deployment.

Both fistulas output reduced dramatically in progress, and the patient was allowed to drink fluids freely. Fluids and electrolytes disturbances were reduced, sepsis attacks were also reduced, oral feeding improved, and the patient started to have regular well-formed bowel motions. After one month of this management, the patient's condition was good enough to tolerate surgery, and adequate time was given for intra-abdominal inflammation to recover. During the definite surgery, we removed the two metal stents and resected the fistulated segment of the jejunum. The small bowel was anastomosed, and the abdomen closed. The patient recovered well after this surgery, discharged home one week after surgery with good oral food intake and good bowel motion. Over one year follow up as an outpatient, the patient remained well and gained his usual weight and physical activities.

DISCUSSION

Postoperative enteral leaks and fistulas are severe and complex, potentially catastrophic postoperative complications with high morbidity and mortality rates. Most (75 to 90%) ECFs are iatrogenic (postoperative or post-procedural) [4]. Half of these are caused by anastomotic leak or dehiscence, and half by inadvertent enterotomy [5]. The diagnosis of an ECF is usually made by visualizing the drainage of succus from the operative incision or a drain site. Alternatively, a fistula may arise with an overt wound infection; enteric contents are found upon opening the surgical wound.

The postsurgical abdomen after laparotomy has dense adhesions and a friable edematous bowel. These changes after surgery make reoperation difficult and increase the chance of injuries and further complications. The abdomen complicated by ECF and sepsis after laparotomy shows a dense fibro-adhesive reaction from ~10 days to 6 weeks or longer [4]. Avoidance of reoperation at this time, when possible, is imperative. Medical supportive therapy with sepsis control and nutritional support should be initiated to allow the abdominal organs to recover. In the absence of distal obstruction or other complicating factors such as

inflammatory bowel disease, neoplasm in the fistula tract, foreign bodies in or near the fistula tract, radiation enteritis, untreated infection, epithelialization of the tract, or mucocutaneous continuity, most ECFs heal spontaneously with conservative therapy, with the majority close by 12 weeks [6-8].

For surgical management of non-healing cases to be successful, the patient must be medically and nutritionally optimized, and these preoperative requirements may take several months to fulfill. Furthermore, the medical management of these patients can be very complex, especially in patients with high output proximal fistulas, which makes maintaining the patient's nutritional status and fluid-electrolyte balance very challenging. In addition, in cases where the fistula is discovered upon opening a midline wound for presumed wound infection, as in our patient, the fistula is already situated in a large, open abdominal wound which significantly complicates the management of the fistula effluent.

The fistula effluent can be acidic or alkaline, depending on its origin, at high volume, or with stasis on the skin; excoriation can occur very fast. Stoma appliances and other output control techniques become more complicated when the skin is raw, uncomfortable, and weeping. Enzymes in the succus can digest the abdominal wall and result in a large wound with a fistula at its center. One of the significant benefits of using the covered metallic stents, in this case, was the better control of the fistula effluent and skin excoriation relief.

In this patient, no enteral feeding could not be given. Furthermore, while most fistula openings healed with nonoperative management, two large fistulas remained with a high output of proximal bowel content. This effluent is alkaline and rich in pancreatic enzymes, causing persistent severe fluid electrolytes disturbances and skin excoriation despite optimal care efforts. As the patient was still not ready for surgical treatment, covered metallic stents were utilized to control the succus leak. Two large-diameter stents are used to manage the remaining two large fistulas to temporarily

restore bowel continuity, allow oral feeding, reduce fluid and electrolytes disturbances, and reduce skin excoriations. Significant reduction of fistulas output allowed skin excoriations to recover and made wound care and fluid electrolytes management easier. The patient was allowed to drink nourishing fluids, which improved his mood and helped build his nutrition and rehabilitate his bowel. However, despite the benefits achieved, both fistulas failed to close. Eventually, surgery was needed to resect the fistulated bowels and restore the bowel continuity. This surgery was performed when the patient was medically and nutritionally optimized, and adequate time was given for intra-abdominal inflammation to recover.

A multidisciplinary approach to gastrointestinal leaks, including therapeutic endoscopy, plays an essential role in management by offering a minimally invasive modality of tackling these problems. The clinical applications for endoluminal stent placement continue to expand and have become a versatile and clinically beneficial tool along the entire gastrointestinal tract. While it was initially used to manage esophageal, gastroduodenal, and malignant colonic obstruction, gastrointestinal stents' clinical indication expanded to include endoscopic treatment of fistula and leaks [2]. They are employed to close leaks and fistulae to prevent extraluminal flow and promote healing. SEMS successfully used for esophageal perforation and anastomotic complications, such as esophagojejunostomy leak and stricture. Furthermore, covered SEMS further expanded to be used in different settings like managing bariatric surgery complications such as gastric sleeve leak and Roux-en-Y gastric bypass anastomotic leak and stricture and colorectal surgical complications.

SEMS come in various lengths and diameters, and most have a proximal and distal flare to prevent migration. We used partially covered metals stent to reduce stent migration in this patient.

Endoscopic control of enterocutaneous fistula has been described using different techniques [3, 9-10], aiming to control fistula, optimize nutrition and optimize

patients to help them recover. Melich G et al. describe the control of enterocutaneous fistula by dual intussusception stent technique [3]. Melich G et al.'s approaches involve inserting two covered overlapping stents endoscopically, one proximal and one distal to the fistula, with 2 cm of each stent protruding cutaneously. The proximal stent is crimped and intussuscepted into the distal stent with an appropriate overlap. Both stents were fixed to the abdominal wall using a prolene suture passed through the anterior wall of both stents. We believe that the technique described in this report is easy and safe to use. The stents can be deployed percutaneously under fluoroscopic and/or endoscopic control.

CONCLUSION

Large high-output enterocutaneous fistulas are complex life-threatening conditions with great difficulties, especially in recent surgery, nutritional depletion, and compromised skin integrity. As shown in this report, the covered self-expanding metal stents can help control this type of fistulas, facilitate wound care, nutritional support, sepsis control, and medical management, optimizing intra-abdominal and systemic conditions for substantial surgical reconstruction.

Ethics approval and consent to participate

Our institution does not require ethical approval for reporting individual cases or case series.

Consent for publication

Written informed consent was obtained from the patient(s) for their anonymized information published in this article.

Author's contribution :

Khaled Demyati: conceptualization, writing-original draft, data curation, formal analysis, investigation, methodology, project administration, resources, software, supervision, validation, visualization, and writing review & editing. **Wael Sadaqa:** writing review & editing. **Iyad Maqboul:** writing review & editing. **Alaa Rustom:** writing review & editing.

Competing interest

The author(s) declared no potential conflicts of interest concerning this article's research, authorship, and publication.

Funding

The author(s) received no financial support for this article's research, authorship, and publication.

Acknowledgments

The authors are very thankful to the surgical team, Intensive care team, radiology department team, and physiotherapy unit at our hospital for providing support for completing this report.

REFERENCES

- 1) ASGE Technology Committee, Varadarajulu S, Banerjee S, *et al.* Enteral stents. *Gastrointest Endosc.* 2011; 74(3): 455-464. doi:10.1016/j.gie.2011.04.011.
- 2) Dabizzi E, Arcidiacono PG. Update on Enteral Stents. *Curr Treat Options Gastroenterol.* 2016; 14(2): 178-184. doi:10.1007/s11938-016-0087-x.
- 3) Melich G, Pai A, Balachandran B, Marecik SJ, Prasad LM, Park JJ. Endoscopic control of enterocutaneous fistula by dual intussuscepting stent technique. *SurgEndosc.* 2016; 30(9): 4150-4151. doi:10.1007/s00464-015-4636-5.
- 4) Galie KL, Whitlow CB. Postoperative enterocutaneous fistula: when to reoperate and how to succeed. *Clin Colon Rectal Surg.* 2006; 19(4): 237-246. doi:10.1055/s-2006-956446.
- 5) Berry SM, Fischer JE. Classification and pathophysiology of enterocutaneous fistulas. *Surg Clin North Am.* 1996; 76(5): 1009-1018. doi: 10.1016/s0039-6109(05)70495-3.
- 6) Makhdoom Z A, Komar M J, Still C D. Nutrition and enterocutaneous fistulas. *J ClinGastroenterol.* 2000; 31:195–204.
- 7) Memon A S, Siddiqui F G. Causes and management of postoperative enterocutaneous fistulas. *J Coll Physicians Surg Pak.* 2004;14:25–28.
- 8) Kaushal M, Carlson G L. Management of enterocutaneous fistulas. *Clin Colon Rectal Surg.* 2004;17:79–88.
- 9) Shehab H. Enteral stents in the management of post-bariatric surgery leaks. *SurgObesRelat Dis.* 2018; 14(3): 393-403. doi: 10.1016/j.soard.2017.12.014.
- 10) Nikfarjam, M. Champagne B, Reynolds HL, Poulouse BK, Ponsky JL, Marks JM. Acute management of stoma-related colocutaneous fistula by temporary placement of a self-expanding plastic stent. *SurgInnov.* 2009; 16(3): 270-273. doi:10.1177/1553350609345851.