



Successful Lengthening of Skin Defect with Ilizarov Technique for Complex Open Calcaneus Fracture with Osteomyelitis

Ali Abukhaled^{1,2}, Mohammad Taleb Abed^{1,2}, Omar Younis^{1,2}, Ayman Alkhawaja^{1,2}, Mazen Abdalla^{1,2*} ,
Mohammad M. Jaber^{1,2*} 

Type: Case Report. Received: 8th Jan. 2025, Accepted: 28th Feb, 2025, Published: 1st Jun. 2026,
DOI: <https://doi.org/10.59049/2790-0231.11.2.2573>

Abstract: Background: A 53-year-old diabetic female had suffered serious injury, an open calcaneal fracture and anterior superior L1 end plate fracture, in the fall from height. Her first treatment has taken care of her wound infection and debridement. **Case Presentation:** She was referred to our tertiary care facility three weeks following injury. Surgical debridement was conducted here and tissue culture established the diagnosis of *Enterococcus faecalis* osteomyelitis. Intravenous antibiotic brought a significant reduction in C-reactive protein. A 4x10cm soft tissue defect closed in 30 days using the Ilizarov external fixation device. **Conclusion:** Soft tissue defect was well-managed through the Ilizarov procedure with respect to results relating to wound healing, sensory improvement, and mobile stability of patient.

Keywords: Calcaneal Fracture, Osteomyelitis, Skin Lengthening, Ilizarov, Palestine.

Introduction

Open calcaneus fractures often result from high-energy mechanisms and are accompanied by concomitant orthopedic and systemic damage. Healthcare professionals must distinguish between open and closed fractures and pay particular attention to the related injuries that occur along with this disease [1]. Open calcaneal fractures are prone to serious infections despite the use of a thorough prevention-focused treatment plan [2]. In orthopedic surgery, the Ilizarov method is a circular external fixation technique used to lengthen or reconstruct limb bones. It manages difficult fractures, open fractures, and instances of infected nonunion that cannot be properly treated with other techniques in a way that spares limbs. The Ilizarov method has shown major improvements since its inception in the middle of the 20th century, emerging as a dependable treatment for bone lengthening, correction of severe deformities, and management of bone abnormalities [3,4]. According to recent reports, a skin stretching device has been successfully utilized to gradually stretch the skin and bring the borders of wounds together, either right away after an injury or later on. In order to treat a skin defect on the foot, we modified this procedure, depending on the idea of skin elongation found in previous literature [5].

Case Presentation

A 53-year-old diabetic female patient was admitted to the hospital following a fall from a standing position at a height of approximately 4 meters. Physical and radiological examination indicated an open fracture in the right calcaneus and an anterior superior L1 end plate burst fracture. Due to wound infection, the patient underwent dressing and debridement under general anesthesia, and she was then referred to our facility for further management.

After 3 weeks, the patient was referred to our hospital which is a tertiary center where she underwent surgery for debridement

under general anesthesia and vacuum application (Figure 1A). Tissue biopsy and culture were undertaken during this surgery, which revealed osteomyelitis upon histological evaluation. The bacterium isolated was identified as *Enterococcus faecalis*.

Later on, the same day of the surgery, the patient was started on intravenous antibiotics (Tigecycline and Ciprofloxacin) following surgery. C-reactive protein (CRP) levels dropped from above 100 at admission to 20, indicating a good response to the debridement and antibiotic treatment.

Operative technique

After 8 days, of attending to our hospital vacuum was removed (Figure 1D), the Ilizarov was applied due to the considerable soft tissue loss in order to use it to lengthen the skin to close the soft tissue defect. Two rings were placed on the tibia and frame for foot, olive wires were used to reduce and fix the calcaneal fracture, along with wires attached to the skin margins for subsequent skin lengthening (Figure 1B,1C).

Technique for skin lengthening and post-operative care

On the first postoperative day, the lengthening began at a pace of 2-3 mm every day according to skin tolerance, the size of the defect was approximately (4*10 cm). We managed to close the defect in 30 days (Figure 2). Daily dressing changes were performed, revealing a clean wound with healthy edges, and the patient received daily physiotherapy. The skin defects progressively decreased, depending on the injured limb's circulation and the color, warmth, suppleness, and capillary responsiveness of the wound skin. Patients recovered satisfactorily, leaving a circular scar, with no signs of infection or tissue necrosis, and sensory improvement was evaluated (Figure 3). As the patient's condition improved, she was able to mobilize out of bed with stable gait.

1 Department of Medicine, Faculty of Medicine and Allied Medical Sciences, An-Najah National University, Nablus 44839, Palestine.

2 Department of Orthopedic Surgery, An-Najah National University Hospital, Nablus 44839, Palestine

* Corresponding authors: *Mazen Abdalla: mazen.abdalla@najah.edu; *Mohammad M. Jaber: m.mazouz@najah.edu

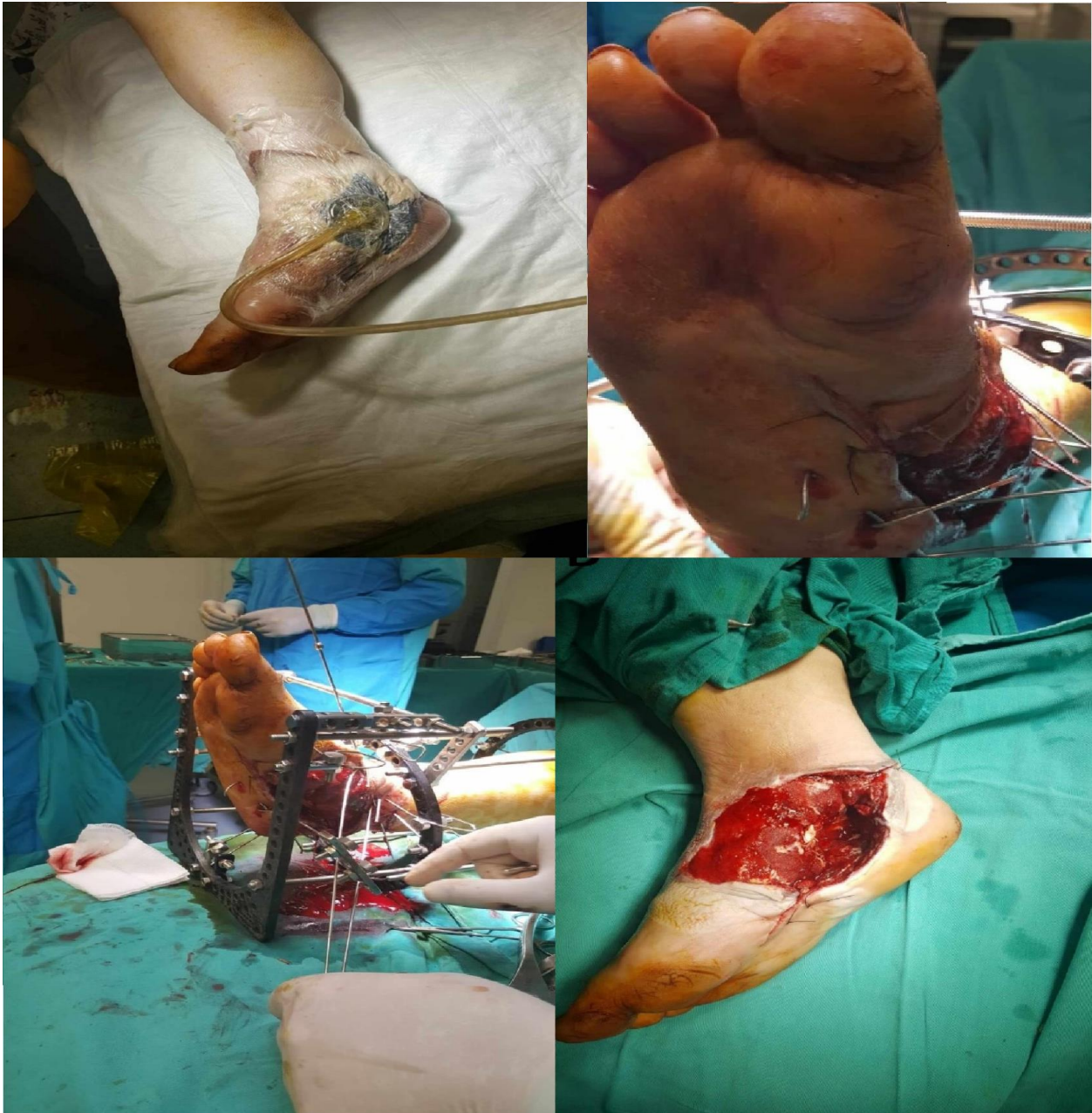

Figure (1): (A) vacuum applied. (B) Classic Ilizarov ring fixator application, plantar view. (C) Medial view. (D) The defect after removal of the vac and debridement.

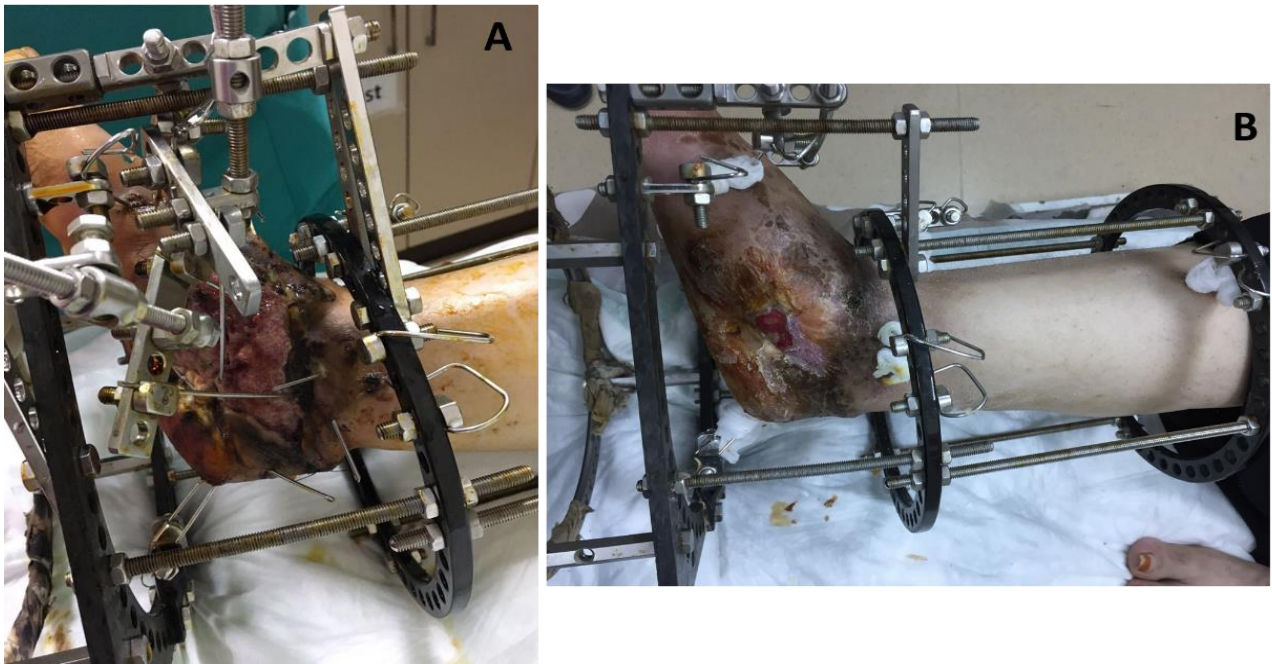


Figure (2): (A) Classic Ilizarov ring fixator application. (B) 30 days post-op showing the defect were appropriate close, Medial view.

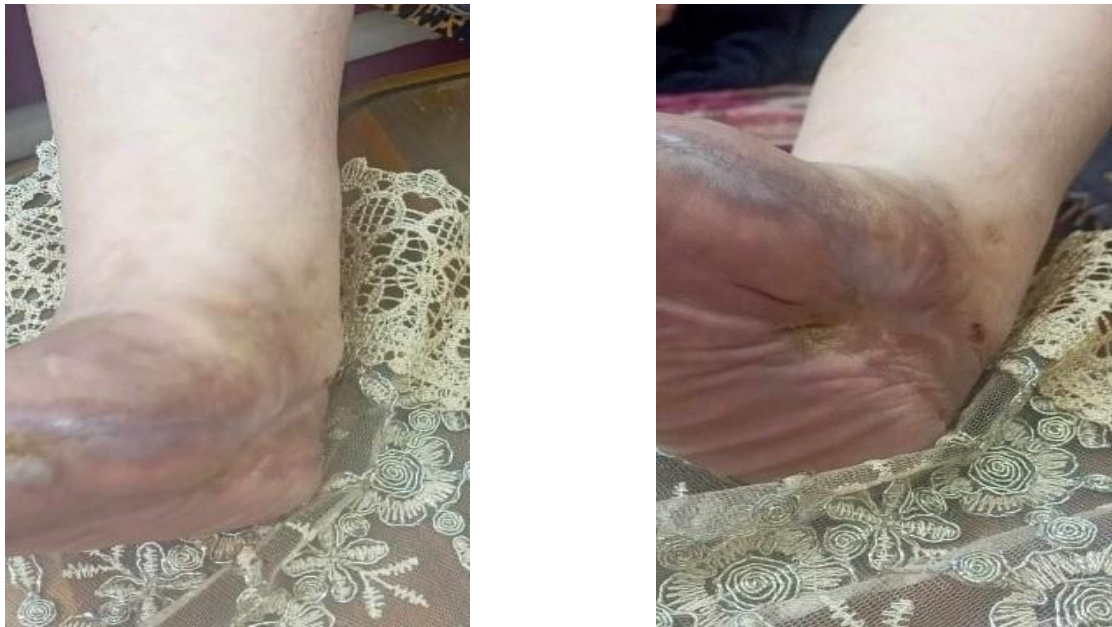

Figure (3): (A) Recent photo of healed foot, Anterior view. (B) Medial view.

Discussion

Open fractures are injuries that occur when a broken bone or fracture hematoma is exposed to the outside environment [6]. The main mechanism of damage is high energy trauma, with falls from great heights or motor vehicle accidents accounting for more than half of the occurrences [7]. The incidence of open fractures was expected to be 11.5 per 100,000 person-years worldwide. The incidence, however, varied between nations and regions, from 2.0 to 48.6 per 100,000 person-years [8].

The calcaneus is the largest tarsal bone and serves to support the body [9]. Calcaneal fractures account for roughly 1-2% of all fractures and 60% of tarsal bone fractures [10]. Injury mechanisms can range from high-energy trauma (falls from great heights) to low-energy trauma (sport). Osteoporosis, diabetes, peripheral neuropathy, osteomalacia and long-term

immunosuppressive medication are also risk factors for this kind of fracture [11].

These fractures are frequently accompanied with other potentially fatal disorders, posing hazards such as neurovascular injuries, connective tissue tearing, site contamination, and skin degloving [7]. In addition, open wounds can be complicated by Infection, pain, and being uncomfortable may all arise from; therefore, the skin defects need rapid repair procedures in order to rebuild their initial structure and prevent the complications. Wound healing is a complicated process that involves replacing the damaged layer of skin with scarring and epithelializing to establish wound boundaries. The dermal elastic fiber pattern has a significant impact on the overall appearance of the repaired skin [12,13].

Multiple surgical procedures are used for treatment of wounds, especially large wounds, like local flaps and free tissue flaps. However, these techniques, are frequently linked to more expensive, prolonged hospital stays, lengthy operating times, severe donor site morbidity, and more complicated surgical procedures [14]. In comparison of skin lengthening technique which has less complication, quite affordable, no increase in treatment time because lengthening of the skin occurs simultaneously with treating the open fracture, and the main point is applied on skin with low vascularity. The Ilizarov procedure, can be used to do this [15].

The Ilizarov technique is a medical procedure for limb lengthening, deformity correction, and the treatment of non-healing fractures. It utilizes an external frame with surgically connected metal rings, wires, and pins to the bone, giving stability and enabling for progressive modification over time [16]. This procedure can be used to lengthen bones that are shorter than normal as a result of congenital abnormalities, growth problems, or severe accidents, as well as to repair angular deformities and heal specific bone infections [17]. Also, it enables effective therapy while limiting potential risks related to employing skin transplants from outside sources by lengthening the patient's own skin, along with bone and soft tissue if necessary. However, the effectiveness of this method may vary based on the unique features of the skin defect and the patient's general health [5].

This case showcases the complications in managing a diabetic patient suffering from an open comminuted calcaneal fracture with osteomyelitis due to *Enterococcus faecalis* and marked soft tissue loss. The flexible application of the Ilizarov frame, which was used for both fracture fixation and gradual skin expansion, offers a valuable solution for soft tissue deficiency. This case demonstrates the value of integrating orthopedic reconstruction with aggressive infection control and post-operative rehabilitation.

In a similar case [5], A 19-year-old male patient had a distal two-thirds skin defect on his leg, exposing necrotic muscles and devitalized tibia. After wound debridement twice, a circumferential loss of 15 cm was found, leaving a 10 cm bone defect. The limb was anesthetized distal to the skin loss. A skin graft was implanted after four days, but due to limited vascularity, the graft took well in the proximal area but only 10% in the distal area. The patient's condition required further treatment. A skin lengthening surgery was scheduled after three weeks due to skin breakage. Skin staples were used to secure the skin to an Ilizarov ring, which was then joined using nylon sutures. The patient gradually stretched the skin, achieving an extension of 8 cm. However, a small patch was obstructed by Schanz screws, requiring a skin graft. The traction device was withdrawn, and the patient's foot sensation was restored. Skin lengthening techniques, like tissue expansion, use mechanical stretching to elicit the adaptive response of the skin. This stimulates cellular proliferation by activating Mechan transduction pathways, thereby making the keratinocyte and fibroblast more active. Moreover, in order to remodel the extracellular matrix, mechanical tension induces collagen synthesizing and increases tissue elasticity. Angiogenesis also is stimulated, ensuring an adequate blood supply to the form-new skin with new stimulation. There occur histological changes in the epidermal and dermal layers of skin, such that new skin forms, in color, texture, and

thickness closely resembling the surrounding tissue. These methods work together to allow effective skin regeneration in support of reconstruction [18,19].

Conclusion

The Ilizarov technique appears to be an effective method for skin lengthening in cases where there is a large amount of lost soft tissue, particularly in cases of complex injuries such as open calcaneal fractures associated with osteomyelitis. Also, it allows closure of large skin defects by creating a type of expander with gradual skin stretching. It allows the closure of even large skin defects in areas of compromised vascularity. It allows controlled expansion of the skin using the Ilizarov frame and closure of the defect without the need for skin grafts, which themselves can be complicated by poor vascularity. We recommend using the Ilizarov technique for skin lengthening in patients with large soft tissue defects for whom other reconstructive options are less viable or may afford higher complication rates. The technique is safe, cost-effective, and far less invasive compared to surgical closure techniques, and thus can be combined with fracture management while curtailing treatment time for the patient.

Disclosure Statement

- **Ethics approval and consent to participate:** The research adhered to the at An - Najah National University Institutional Review Board's (IRB) ethics and guidelines. The patient agreed to participate verbally. The gathered data was securely stored so that only the research analysts and lead investigators could access it, protecting patient privacy. Names of patients were not kept on file. The primary investigators appropriately preserved the data after the study was over, which could be useful in upcoming related or comparable investigations.
- **Consent for publication:** The patient agreed to participate ad case publication verbally.
- **Availability of data and materials:** The dataset supporting the conclusions of this article is available upon request from the corresponding author.
- **Author's contribution:** The authors have contributed to the manuscript as follows: M J, and M A: The principal investigator optimized the study proposal and protocol, supervised the data analysis, and edited the final manuscript file. A A, M A, and O Y participated in the study writing, data collection, and wrote the first draft of the manuscript. A A: revised the study protocol and assisted in project supervision. All the authors read and approved the final manuscript.
- **Conflicts of interest:** All the authors declare that they have no competing interests.
- **Funding:** None.
- **Acknowledgements:** The authors would like to acknowledge the patient who agreed to join the study and would like to thank An-Najah National University (www.najah.edu) for the technical support.

Open Access

This article is licensed under a Creative Commons Attribution 4.0 International License, which permits use, sharing, adaptation, distribution and reproduction in any medium or format, as long as you give appropriate credit to the original author(s) and the source, provide a link to the Creative Commons licence, and indicate if changes were made. The images or other third party material in this article are included in the article's Creative Commons licence, unless indicated otherwise in a credit line to the material. If material is not included in the article's Creative Commons licence and your intended use is not permitted by statutory regulation or exceeds the permitted use, you will need to obtain permission directly from the copyright holder. To view a copy of this license, visit <https://creativecommons.org/licenses/by-nc/4.0/>

Reference

- 1] Worsham JR, Elliott MR, Harris AM. Open Calcaneus Fractures and Associated Injuries. *J Foot Ankle Surg* [Internet]. 2016 Jan 1 [cited 2025 Feb 18];55(1):68–71. Available from: <https://pubmed.ncbi.nlm.nih.gov/26243720/>
- 2] Heier KA, Infante AF, Walling AK, Sanders RW. Open fractures of the calcaneus: soft-tissue injury determines outcome. *J Bone Joint Surg Am*. 2003 Dec;85(12):2276–82.
- 3] Kouzelis A, Vrachnis IN, Vris A, Zampakis P, Kokkalis ZT, Panagopoulos A. A Novel Treatment of a 65-Year-Old Woman with a Neglected Type IIIB Open Fracture of the Tibia with Inadequate Soft Tissue Coverage and Periosteal Stripping Requiring an Ilizarov Approach to Bone and Soft Tissue Lengthening and Reconstruction: A Case Report and Review of the Literature. *Am J Case Rep* [Internet]. 2020 [cited 2025 Feb 18];21:1–6. Available from: <https://pubmed.ncbi.nlm.nih.gov/33279928/>
- 4] Ilizarov Method for Bone Lengthening and Defect Management Review of Contemporary Literature - PubMed [Internet]. [cited 2025 Feb 18]. Available from: <https://pubmed.ncbi.nlm.nih.gov/27281320/>
- 5] Madhuri V, Kurpad SR, Nithyananth M, Jepegnanam TS, K Titus VT, Dhanraj P. Circumferential skin defect-Ilizarov technique in plastic surgery. 37:5.
- 6] Open Fracture Management - PubMed [Internet]. [cited 2025 Feb 18]. Available from: <https://pubmed.ncbi.nlm.nih.gov/28846249/>
- 7] Elniel AR, Giannoudis P V. Open fractures of the lower extremity: Current management and clinical outcomes. *EFORT open Rev* [Internet]. 2018 May 1 [cited 2025 Feb 18];3(5):316–25. Available from: <https://pubmed.ncbi.nlm.nih.gov/29951271/>
- 8] Alhawas A, Alghamdi M. Epidemiology, Etiology, Timing and Severity of Open Fracture - a Five Years Review From a Tertiary Trauma Center, Eastern Province, Saudi Arabia. *Med Arch (Sarajevo, Bosnia Herzegovina)* [Internet]. 2023 [cited 2025 Feb 18];77(5):391–5. Available from: <https://pubmed.ncbi.nlm.nih.gov/38299093/>
- 9] Angin S, Demirbüken İ. Ankle and foot complex. *Comp Kinesiol Hum Body Norm Pathol Cond*. 2020 Jan 1;4:11–39.
- 10] Daftary A, Haims AH, Baumgaertner MR. Fractures of the calcaneus: a review with emphasis on CT. *Radiographics* [Internet]. 2005 Sep [cited 2025 Feb 18];25(5):1215–26. Available from: <https://pubmed.ncbi.nlm.nih.gov/16160107/>
- 11] Galluzzo M, Greco F, Pietragalla M, De Renzis A, Carbone M, Zappia M, et al. Calcaneal fractures: radiological and CT evaluation and classification systems. *Acta Biomed* [Internet]. 2018 Jan 1 [cited 2025 Feb 18];89(1-S):138–50. Available from: <https://pubmed.ncbi.nlm.nih.gov/29350643/>
- 12] Park K-S, Lee W-S, Ji S-Y, Yang W-S. The treatment of post-traumatic facial skin defect with artificial dermis. *Arch craniofacial Surg* [Internet]. 2018 Mar 20 [cited 2025 Feb 18];19(1):35–40. Available from: <https://pubmed.ncbi.nlm.nih.gov/29609430/>
- 13] Juhasz I, Kiss B, Lukacs L, Erdei I, Peter Z, Remenyik E. Long-term followup of dermal substitution with acellular dermal implant in burns and postburn scar corrections. *Dermatol Res Pract* [Internet]. 2010 [cited 2025 Feb 18];2010(1). Available from: <https://pubmed.ncbi.nlm.nih.gov/21234359/>
- 14] Wu Q, Shao Z, Li Y, Rai S, Cui M, Yang Y, et al. A novel skin-stretching device for closing large skin-soft tissue defects after soft tissue sarcoma resection. *World J Surg Oncol* [Internet]. 2020 Sep 17 [cited 2025 Feb 18];18(1):1–8. Available from: <https://wjso.biomedcentral.com/articles/10.1186/s12957-020-02022-3>
- 15] Lerner A, Ullmann Y, Stein H, Peled IJ. Using the Ilizarov external fixation device for skin expansion. *Ann Plast Surg* [Internet]. 2000 [cited 2025 Feb 18];45(5):535–7. Available from: <https://pubmed.ncbi.nlm.nih.gov/11092365/>
- 16] Ilizarov principles of deformity correction - PMC [Internet]. [cited 2025 Feb 18]. Available from: <https://pmc.ncbi.nlm.nih.gov/articles/PMC3025247/>
- 17] Malkova TA, Borzunov DY. International recognition of the Ilizarov bone reconstruction techniques: Current practice and research (dedicated to 100th birthday of G. A. Ilizarov). *World J Orthop* [Internet]. 2021 [cited 2025 Feb 18];12(8):515–33. Available from: <https://pubmed.ncbi.nlm.nih.gov/34485099/>
- 18] Wollina U, Berger U, Stolle C, Stolle H, Schubert H, Zieger M, et al. Tissue expansion in pig skin—a histochemical approach. *Anat Histol Embryol* [Internet]. 1992 [cited 2025 Feb 19];21(2):101–11. Available from: <https://pubmed.ncbi.nlm.nih.gov/1497138/>

19] Guo Y, Song Y, Xiong S, Wang T, Liu W, Yu Z, et al. Mechanical Stretch Induced Skin Regeneration: Molecular and Cellular Mechanism in Skin Soft Tissue Expansion. *Int J*

Mol Sci [Internet]. 2022 Sep 1 [cited 2025 Feb 19];23(17). Available from: <https://pubmed.ncbi.nlm.nih.gov/36077018/>