

Congenital diverticulum of the gallbladder, a rare anomaly: clinical, radiological, operative, and histopathological features

Khaled Demyati^{1,2}, Asmaa Nayfeh¹, Hanood Abu Rass^{2,3} & Ahmed Awadghanem^{2,4}*

¹ Department of Surgery, An-Najah National University Hospital, An-Najah National University, Nablus, Palestine; ² Department of Medicine, Faculty of Medicine and Health Sciences, An-Najah National University, Nablus, Palestine; ³ Department of Pathology, An-Najah National University Hospital, An-Najah National University, Nablus, Palestine; ⁴ Department of Radiology, An-Najah National University Hospital, An-Najah National University, Nablus, Palestine.

*Corresponding author: khaleddemyati@najah.edu

Received: (28/9/2020), Accepted: (29/6/2021)

ABSTRACT

Congenital diverticula of the gall bladder are considered one of the rarest congenital anomalies of the gall bladder is rarely discussed in the literature, with the incidence estimated to be about 0.0008% of all resected gallbladders. It has an important and distinct anatomical and clinical entity with significant clinical implications. It poses a diagnostic challenge for radiologists and surgeons as it should be differentiated from other types of congenital anomalies and pathological states of the gall bladder. Furthermore, the association of diverticulum with several pathological problems of the gall bladder has been reported in the literature including calculous cholecystitis, cholecystitis cholelithiasis, recurrent cholangitis - and carcinoma of the gallbladder. In addition, it might press upon the adjacent structures such as the duodenum or stomach. Rupture is a rare complication. In this report, we present a case of congenital gallbladder diverticulum that has been initially misdiagnosed as GB lymphangioma and describe our clinical, radiological, operative, and histopathological findings. A 33-year-old female patient was investigated for colicky abdominal pain of eight months' duration. Abdominal U/S showed multiple numerous septa inside the GB, minimal amount of sludge, with no stones. Abdominal CT scan, liver MRI, and MRCP showed that the GB is partially intrahepatic with numerous septated small cystic appearances inside, those features raising the suspicion of GB lymphangioma arising from the lymphatic tissue of the gallbladder wall. The decision for surgery was made, and while adequate surgery can be performed using a laparoscopic approach, we preferred to do open cholecystectomy to achieve complete GB resection and to assess the gallbladder for the presence of suspicious malignant features such as the presence of soft tissue components and hard consistency especially in the GB bed which is hard to assess laparoscopically. Intraoperatively, the GB wall was thin with a lobulated surface with several bulges suggestive of GB diverticulosis. The operation passed smoothly and the postoperative course was uneventful. The diagnosis of the congenital diverticulum was only confirmed by histology. The diverticulum of the gall bladder is an important and distinct anatomical entity with significant clinical implications. Difficulties are still faced in differentiating such rare gallbladder anomalies, it has been associated with several pathological problems in GB and adequate workup is required to differentiate congenital gall bladder diverticulum from other underlying pathologies.

Keywords: Congenital Diverticulum, Gallbladder, Cholecystectomy, Anomalies.

INTRODUCTION

Congenital gall bladder diverticulum should be differentiated from the acquired or pseudo or false variety which is a result of underlying pathology. It is one of the rarest congenital anomalies of the gall bladder being rarely discussed in the literature [1]. The liver, gall bladder, and the biliary ductal system develop from the hepatic diverticulum of the foregut, at the beginning of the fourth week of development. The cranial part is the primordium for the liver and bile ducts, while the caudal part gives rise to the gall bladder and the cystic duct. Any arrest or deviation from the normal developmental process in the intrauterine life results in a type of anomaly of the gallbladder and the biliary system including congenital diverticulum.

The diverticulum of the gall bladder is an important and distinct anatomical entity with significant clinical implications. The diverticulum can be congenital or acquired. The congenital type has all three layers of the gall bladder wall, whereas the acquired variety is a result of the disease process and has little or no smooth muscle in its wall [2].

In this report, we present a very rare case of congenital gallbladder diverticulum that has been initially misdiagnosed as GB lymphangioma, and describe our clinical, radiological, operative, and histopathological findings.

CASE REPORT

A 33-year-old female patient was investigated for colicky abdominal pain of eight months' duration with no other associated GI symptoms. Abdominal U/S showed multiple numerous septa inside the GB, minimal amount of sludge, with no stones. An abdominal CT scan showed multiple gallbladder septations and no other definite liver lesions. These studies were followed by liver MRI and MRCP to further assess the GB and check for

other biliary anomalies. These studies showed that the GB is partially intrahepatic with numerous septated small cystic appearances inside, those features rising the suspicion of GB lymphangioma. Axial T2-weighted image showed an intact partially intrahepatic lumen of the gallbladder (high-signal intensity) with a thin multi-septated cystic mass-like appearance with a scalloping margin which highly suggested a lymphangioma arising from the lymphatic tissue of the gallbladder wall (Figure 1). There were no other biliary anomalies identified, and no radiological features of malignancy.

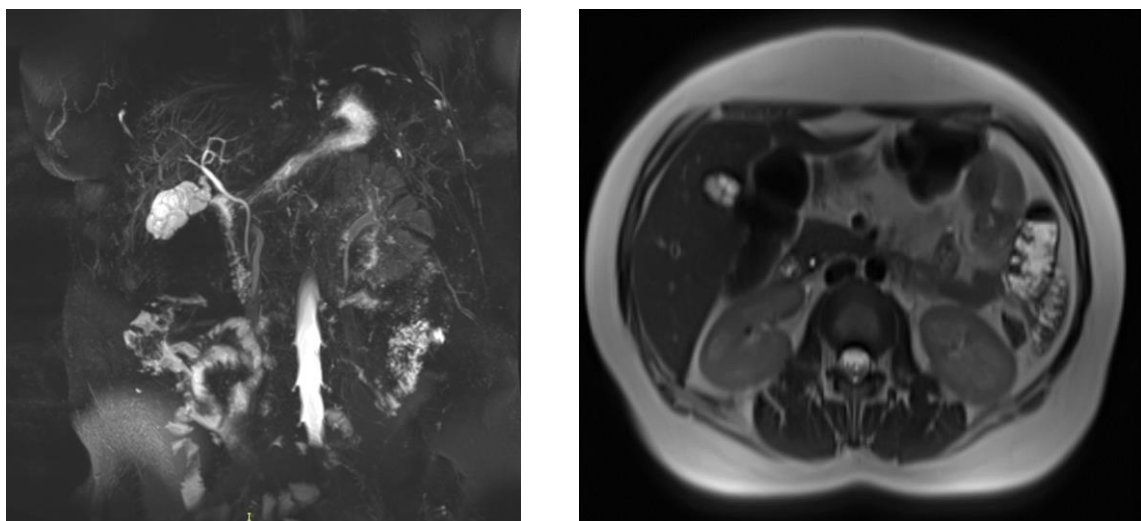


Figure (1): gall bladder with thin multiseptated high-signal intensity cystic mass-like with scalloping margin as seen in image (a) MR cholangiopancreatographic and image (b) Axial T2-weighted magnetic resonance image.

With the diagnosis of gallbladder lymphangioma in mind, we proceeded to open cholecystectomy to achieve complete resection and to assess the gallbladder for the presence of suspicious malignant features. Intraoperatively, the GB

wall was thin with a lobulated surface with several bulges suggestive of GB diverticulosis (Figure 2). The cholecystectomy was technically simple and the postoperative course was uneventful.

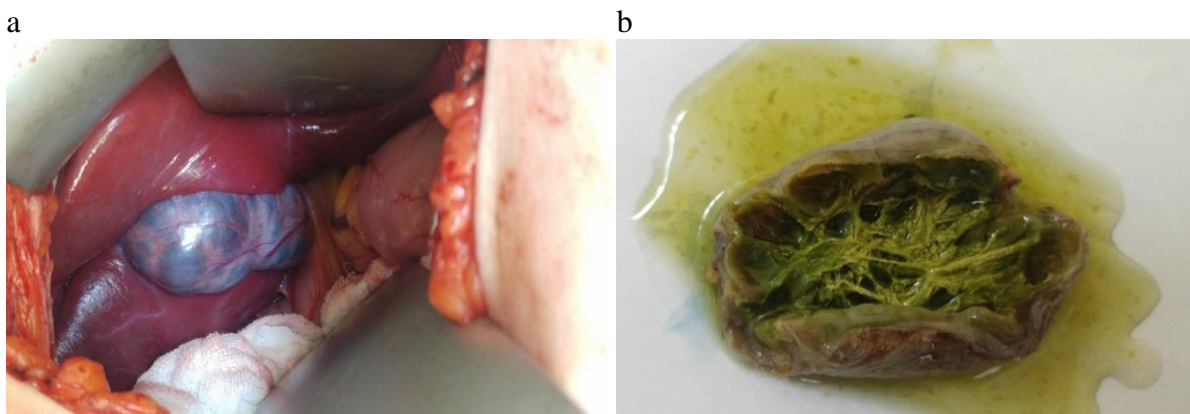


Figure (2: a): GB as seen intraoperatively with thin lobulated surface and several bulges. b) The gross specimen of the GB opened showing the GB diverticulosis from inside. Incomplete septation pinches off small cavities in the lumen of the gallbladder.

The diagnosis of the congenital diverticulum was confirmed by histology. The histopathology examination (Figure 3) showed a specimen consisting of a gallbladder measuring 5.0x2.5x2.0 cm, the wall thickness measures 0.4 cm, with multiple cystic spaces, and an unremarkable liver bed. Interestingly, each cyst is

composed of all normal layers of the gallbladder.

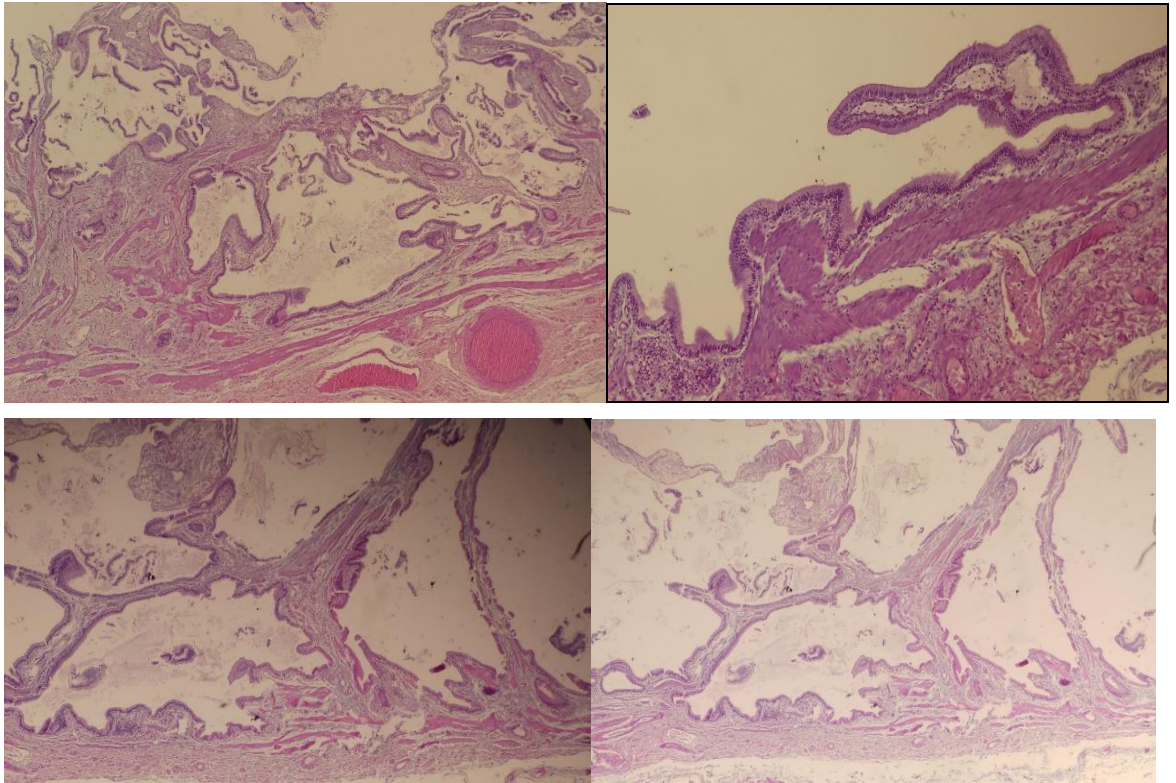


Figure (3): Histopathology examination of the GB wall showing multiple cystic spaces with each having all normal layers of the gallbladder.

DISCUSSION

Congenital diverticula of the gall bladder are considered one of the rarest congenital anomalies of the gall bladder is rarely discussed in the literature. The incidence of congenital diverticula of the gall bladder has been reported from 0.0008% of all resected gallbladders at the Mayo Clinic to 0.06% of a series of congenital anomalies of the gallbladder collected from the world literature [1]. Congenital gallbladder diverticula are also referred to as true diverticula of the gallbladder and must be differentiated from acquired, pseudo, or false diverticula. The differentiation can be made based on the histological features of each when pathologic specimens are available, with true congenital diverticulum retaining all histologic features of the gallbladder [2].

Cases of true diverticula of the gallbladder that were reported previously in the current literature were usually di-

agnosed after surgical resection [3]. Diverticula can occur anywhere along the surface of the gall bladder from the fundus to the neck [1, 2] and can get large before they get medical attention [4]. U/S and MRI are good diagnostic modalities that can suggest the diagnosis [1-5]. However, true congenital diverticula of the gall bladder can be confused with an acquired or pseudo-false variety [5] and should be differentiated from other types of congenital anomalies and pathological states of the gall bladder. Associations of the diverticulum with several pathological problems of the gall bladder have been reported in the literature including calculous cholecystitis, cholecystitis cholelithiasis, recurrent cholangitis - and carcinoma of the gallbladder.

In chronic cholecystitis, these diverticula may display reactive epithelial atypia, which may be quite severe and may be mistaken for invasive carcinoma. On the other hand, many gallbladder car-

cinomas arise in conjunction with cholelithiasis and cholecystitis and may appear deceptively benign [6].

A thin multi-septated cystic mass-like appearance with scalloping margins can sometimes be confused with lymphangiomas arising from the lymphatic tissue of the gallbladder wall [7, 8]. While GB lymphangiomas are usually present in children aged 5 years and younger, most lymphangiomas are diagnosed in adulthood incidentally, because they are asymptomatic until the mass enlarges to cause symptoms [9].

Our patient was initially diagnosed as a case of lymphangioma based on the imaging findings and it was only confirmed later by a histopathological evaluation which showed the presence of all normal layers of the gallbladder in each of the multiple cystic lesions which is consistent with the description of gallbladder congenital diverticulum; in comparison to the lack of presence of these layers in a lymphangioma tissue.

While simple laparoscopic cholecystectomy is adequate and can be performed safely in cases of GB diverticulum, in this case, we preferred to proceed with an open approach, under the presence of diagnostic problems and the suspicion of GB lymphangioma. GB lymphangiomas require complete resection to avoid local recurrence. Furthermore, in an open approach, it is easier to assess the GB for suspicious malignant features such as the presence of soft tissue components in its wall and to assess the consistency of hardness and possible invasion. While carcinoma has been reported before in association with GB diverticulum [2], no strong evidence is available to support this association. However, the GB diverticulum may pose a diagnostic challenge with the GB tumor needing to be excluded.

Our experience with this patient proves the difficulty we still face in differentiating those rare gallbladder anomalies; this could be accounted for by our limited interaction with such rare cases. Furthermore, gall bladder diverticula might be associated with other anomalies and were reported in association with choledocholithiasis [10] and rarely with focal malignancy developed within the diverticulum [2], or may pose a diagnostic challenge to differentiate tumors. This stresses that adequate assessment is mandatory in this type of patient before and during surgery.

REFERENCES

- 1) Rajguru J, Jain S, Khare S, Fulzele RR, Ghai R. Embryological basis and clinical correlation of the rare congenital anomaly of the human gall bladder: - "the diverticulum" - a morphological study. *J Clin Diagn Res.* 2013; 7(10): 2107-2110.
- 2) Chin NW, Chapman I. Carcinoma in a true diverticulum of the gallbladder. *Am J Gastroenterol.* 1988; 83(6): 667-669.
- 3) Doganay S, Kocakoc E, Esen M, Çiçekçi M. True diverticulum of the gallbladder. *J Ultrasound Med.* 2010; 29(1): 121-123.
- 4) Parikh HK, Deshpande RK, Desai PB. Giant gall bladder diverticulum. *Indian J Gastroenterol.* 1991; 10(2): 64-65.
- 5) Lee TH, Park SH, Park JY, Lee CK, Chung IK, Kim HS, et al. Gallbladder pseudodiverticulosis mimicking a multiseptate gallbladder with stones. *Gut Liver.* 2009; 3(2): 134-136.
- 6) Williams I, Slavin G, Cox A, Simpson P, de Lacey G. Diverticular disease (adenomyomatosis) of the gallbladder: a radiological-

- pathological survey. *Br J Radiol.* 1986; 59(697): 29-34.
- 7) Noh KW, Bouras EP, Bridges MD, Nakhleh RE, Nguyen JH. Gallbladder lymphangioma: a case report and review of the literature. *J Hepatobiliary Pancreat Surg.* 2005; 12(5): 405-408.
 - 8) Choi JY, Kim MJ, Chung JJ, Park SI, Lee JT, Yoo HS, et al. Gallbladder lymphangioma: MR findings. *Abdom Imaging.* 2002; 27(1): 54-57.
 - 9) Kim JK, Yoo KS, Moon JH, Park KH, Chung YW, Kim KO, et al. Gallbladder lymphangioma: a case report and review of the literature. *World J Gastroenterol.* 2007; 13(2): 320-323.
 - 10) Garg P, Dass B. Multiple diverticula of gall bladder. *Indian J Gastroenterol.* 1998; 17(1): 32-33.