

Double Major Duodenal Papillae: A Rare Congenital Anomaly identified during Endoscopy, Case Report

Khaled Demyati ^{1,*} & Alaa Rustom ¹

¹ Department of Surgery, An-Najah National University Hospital, An-Najah National University, Nablus, Palestine.

*Corresponding author: Khaleddemiyati@njah.edu

Received: (18/12/2021), Accepted: (19/11/2022). DOI: <https://doi.org/10.59049/2790-0231.1172>

ABSTRACT

The major duodenal papilla is the terminal part of hepatopancreatic drainage. Variations in the bile duct and the main pancreatic duct opening are related to rotation and recanalization, which occurs during embryologic development. A double major papilla of Vater is a congenital anomaly that was rarely described before. We report a 49-year-old man with double papilla of Vater identified during Endoscopic intervention for obstructive jaundice. The patient had symptomatic gallstone disease and presented with biliary colic and obstructive jaundice. During duodenoscopy, the patient was found to have a double major papilla with a larger cranial one located at the expected usual anatomical position of ordinary cases. Canulation of this cranial papilla and injection of contrast medium identified an anatomically normal single common bile duct with stones and dilatation. Sphincterotomy and stone extraction was performed as usual. A literature review of this anomaly is presented. The clinical and endoscopic significance of this anomaly is discussed in detail.

Keywords: Major duodenal papillae, ERCP, Endoscopy, Congenital anomalies, Case report.

INTRODUCTION

The major duodenal papilla is where the junction of the main pancreatic duct and the bile duct (ampulla of Vater) enter the duodenum. The ampulla is surrounded by the sphincter of Oddi, which controls the release of bile and pancreatic fluid into the duodenum. [1].

The first step of endoscopic retrograde cholangiopancreatography (ERCP) is the cannulation of the major papilla. Variations in papillary morphology and biliary and duodenal anatomy are responsible for difficult cannulations and possible complications. Variations in the bile duct and the main pancreatic duct opening are related to rotation and recanalization during embryologic development. Complete non-union of the distal common bile duct and duct of Wirsung gives rise to a double papilla of Vater [1-4].

A double major papilla of Vater is a rare congenital anomaly with few documented cases described in the literature [4-8]. In this report, we describe the case of a 49-year-old man with a double papilla of Vater incidentally identified during endoscopic inter-

vention for obstructive jaundice. A full description of the clinical and endoscopic findings is provided with a literature review of the available data related to this anomaly.

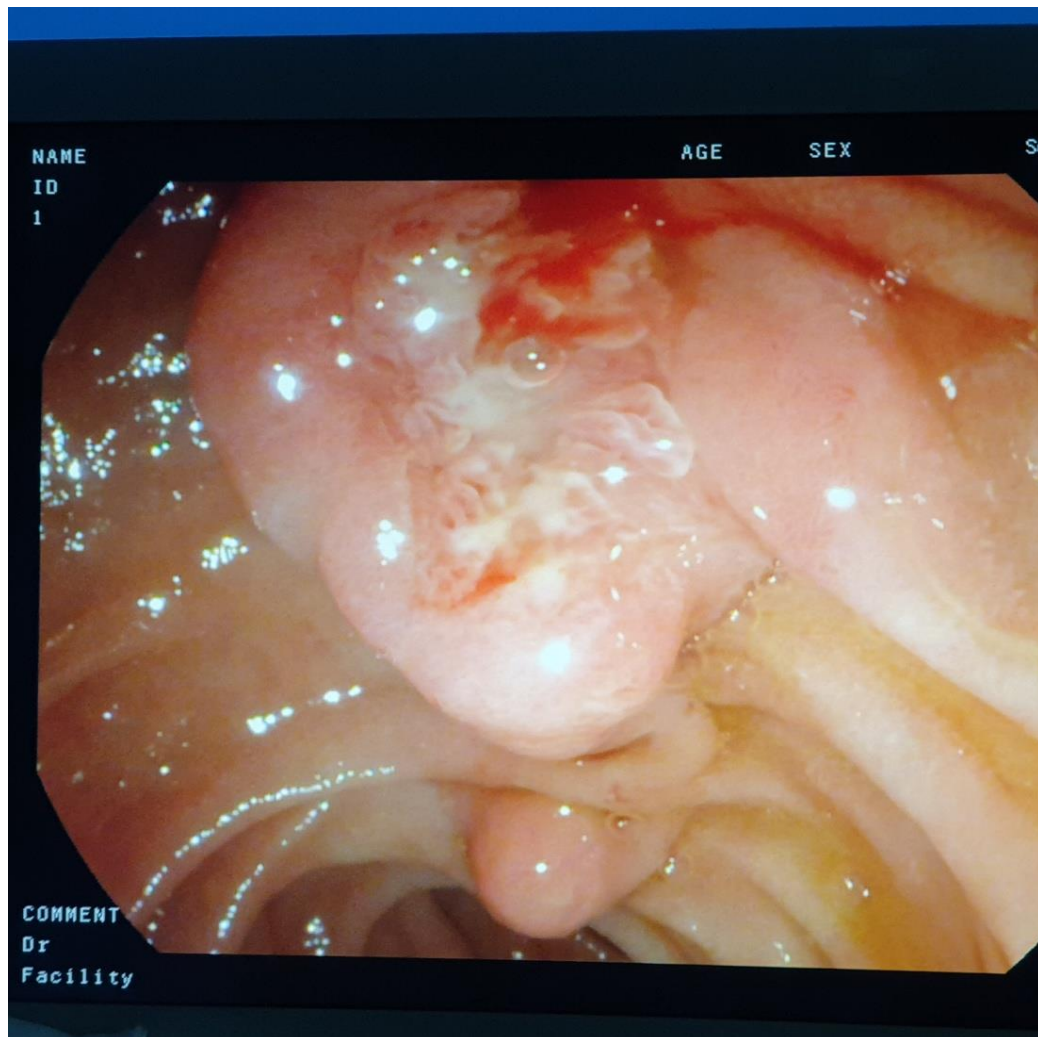
CASE REPORT

A 49-year-old male patient with a free past medical history, apart from a bullet injury in his right leg, presented with abdominal pain for further management. The patient reported recurrent right upper quadrant abdominal pain attacks for several years that were sometimes associated with nausea and vomiting. The patient was diagnosed to have gastritis and was prescribed proton pump inhibitors. The patient presented with epigastric and right upper abdominal pain, which persisted for 12 hours. The pain was stabbing in nature and radiating to the back. It was associated with multiple times of vomiting, diaphoresis, and yellowish discoloration of the skin with dark urine. On examination, the patient was in pain and found to be jaundiced, the patient was not febrile, and the abdominal examination was only remarkable for mild right upper quadrant tenderness. His laboratory workups were only remarkable for obstructive jaundice with direct hyperbilirubinemia, elevated ALT, AST, GGT, and Alkaline phosphatase: TSB: 5.133

mg/dl, DSB: 4.187 mg/dl, Amylase: 45 U/L, Lipase: 47.1 U/L, AST: 189.5 U/L, ALT: 361.7 U/L, GGT: 470 U/L, ALP: 111 U/L. There was no leukocytosis or rise in C-reactive protein level.

Transabdominal ultrasonography showed a distended gallbladder with multiple gallstones. The gallbladder wall was thickened with minimal pericholecystic edema. The visualized proximal CBD and CHD measure 10mm in their largest diameter, associated with mild intrahepatic biliary tree dilatation. ERCP was performed the next day for this patient to manage his obstructive jaundice. A gross inspection of the major papilla showed the presence of a double major papilla [Figure 1]. The major cranial papilla was larger than the caudal papilla and was located in ordinary cases' normal position. It was hemispherical, with the typical circular fold at the oral side(

the hooding fold) and the vertical fold (called the frenulum) at its anal side. The caudal papilla was smaller and located about 2cm distal to the cranial papilla. It resembled the minor papilla in shape but larger. The minor papilla was normal and situated in its usual anatomical position. After cannulating the cranial papilla, the contrast medium was introduced into dilated bile ducts with two small bile duct stones. Endoscopic sphincterotomy was performed, and both bile duct stones were extracted with a basket. No pancreatogram was performed, and no cannulation of the caudal papilla was attempted. No ERCP-related complications occurred after the procedure. The patient was discharged home the next day and scheduled for elective laparoscopic cholecystectomy. His cholecystectomy was performed three weeks later, with an uneventful postoperative course.



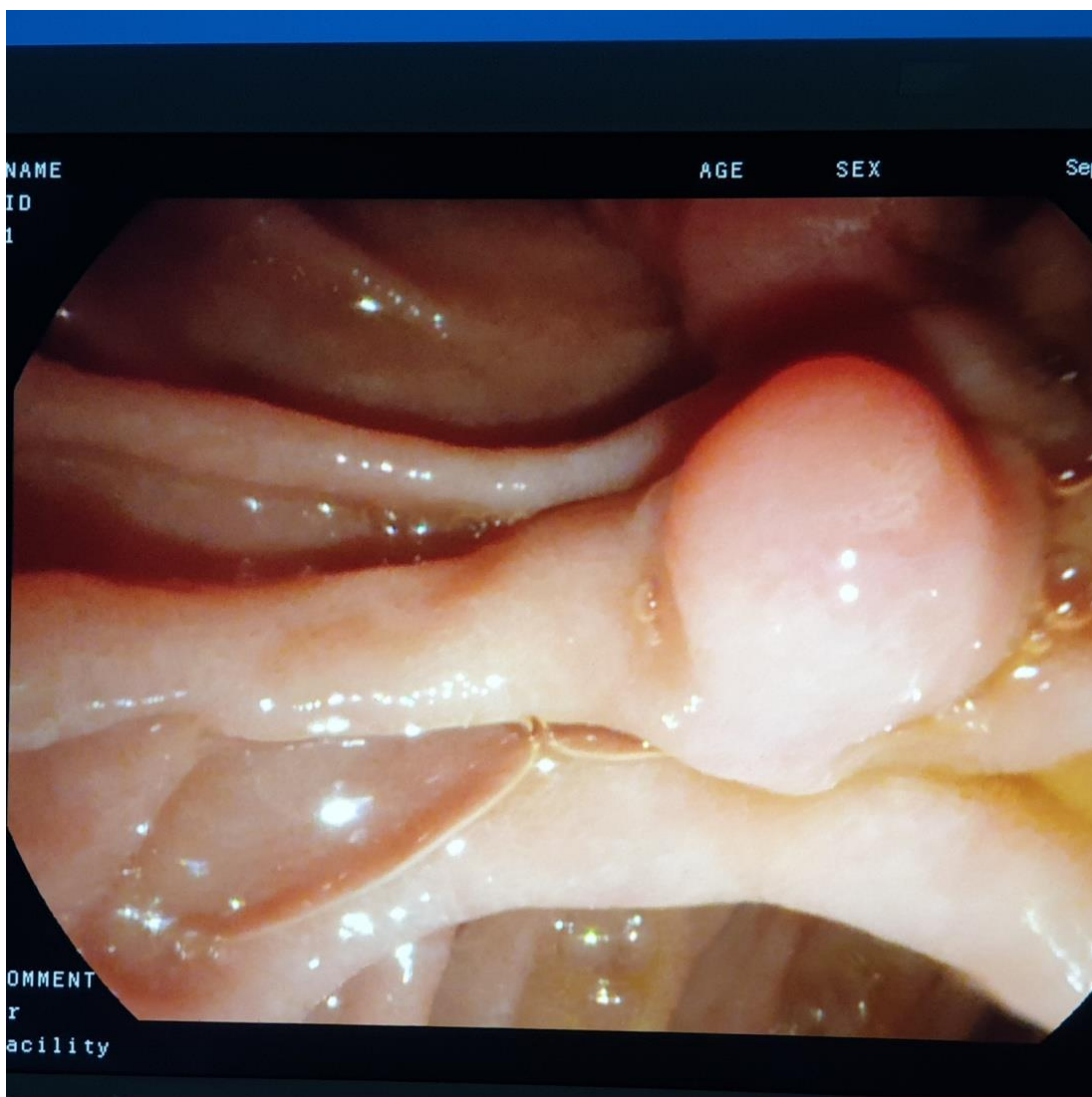


Figure (1): Endoscopic View during ERCP showing double major papilla, cholangiogram performed in the proximal papilla.

DISCUSSION

The major duodenal papilla is the terminal part of hepatopancreatic drainage. The liver, gallbladder, biliary tree, and pancreas originate in the hepatic diverticulum, which develops in the fourth embryonic week. The establishment of the lumen of the extrahepatic biliary tree occurs by recanalization [1]. The common bile duct and the main pancreatic duct coalesce within one duct before opening into the duodenum on the major papilla during recanalization. A double major papilla of Vater is a very rare congenital anomaly. Double openings develop when they fail to coalesce and remain independent ducts that open into the duodenum separately [1-3].

The upper part of the major duodenal papilla, represented by the common bile duct, develops from the terminal part of the foregut; hence it derives its blood supply from the superior pancreaticoduodenal artery. This artery is a distant branch of the celiac trunk, which is the artery of the foregut. On the other hand, the lower end of the normal major duodenal papilla represented by the main pancreatic duct is derived from the midgut, which derives its blood supply from the inferior pancreaticoduodenal artery, a branch of the superior mesenteric artery, which is the artery of the midgut. Hence a normal major duodenal papilla is the main site of arterial anastomosis between the superior mesenteric artery and the celiac trunk. In a study that investigated the arterial blood supply of the papilla, it was

found that the papillary arteries originated from three sources: communicating arteries and the posterior and anterior pancreaticoduodenal arcade arteries. Most arteries were related to the anterosuperior and posteroinferior quadrants of the major duodenal papilla. [8]. While these data describe the pattern of vascular supply to the major papilla, no data is available in the rare cases where double major papillae exist. This anomaly seems to widen the distance between the terminal end of the foregut and the beginning of the midgut with possible effects on the anastomosis between the two arteries.

Identification of double major papillae usually in clinical practice occurs during ERCP. Simon and colleagues described a double papilla of Vater in three of 1600 ERCPs performed at their institution for a 0.18 % incidence [9]. A search in Medline revealed only four documented cases of the double papilla of Vater [3,5,7,9].

In all these reports, the anomaly was incidentally discovered during endoscopy. The anomaly was detected incidentally during esophagogastroduodenoscopy for nausea and vomiting in one report. The double major papilla was seen during ERCP in the remaining three cases. ERCP was performed for sclerosing cholangitis in one patient and obstructive jaundice due to stone disease in the other two patients. There were no complications related to the ERCP in these patients, and it was suggested that this rare anatomic anomaly does not predispose them to any pancreaticobiliary disease [3,5].

In our patient, a gross inspection of the major papilla showed the presence of double major papillae. The major cranial papilla was larger than the caudal papilla and was located in ordinary cases' usual expected normal position. The caudal papilla was smaller and situated about 2cm distal to the cranial one. The relation of the major cranial papilla to the common bile duct and the caudad orifice to the duct of Wirsung remains a constant finding in all reports [3-9].

The presence of another papilla in the duodenum should also raise the possibility of a double common bile duct. A double common bile duct is a rare congenital anomaly in which two common bile ducts exist. One usually has

normal drainage into the major papilla, and the other duct opens in different parts of the upper gastrointestinal tract (stomach, duodenum, main pancreatic duct, or septum) [10]. Tealium identified 24 cases in western literature until 1986 [11]. On the other hand, Yamashita found 47 patients with this anomaly in the Japanese literature from 1968 to 2002 [12].

Another related anomaly of the major papilla is the presence of two separate orifices for a single major papilla. It was described as a rare anatomic variant. [4,6,13] In this anomaly, the cranial orifice communicates with the common bile duct, and the caudad orifice communicates with the duct of Wirsung, a relation that was a constant finding in all reports [6]. This anomaly differs from the double major papilla anomaly, where two independent papillary structures drain the biliary and the main pancreatic ducts separately [7].

Misidentification of this variant may end with cannulating the wrong papilla. Inadvertent cannulation of the pancreatic duct increases the risk of ERCP-induced pancreatitis [14]. Hence, it is crucial to understand and recognize this anomaly to avoid procedure-associated complications and unnecessary repeated procedures.

CONCLUSION

Our case demonstrates the unusual finding of double papillae of Vater during endoscopic intervention for obstructive jaundice. In this case, the relation of the major cranial papilla to the common bile duct and the caudad orifice to the duct of Wirsung was consistent with the findings in all other reports. The major cranial papilla was related to the common bile duct, while the caudad orifice was associated with the duct of Wirsung.

Ethics approval and consent to participate

This is a retrospective case report, with no patient participation and no consent or ethical approval required.

Consent for publication

We now consent to the Publisher (Palestinian Medical and Pharmaceutical Journal (Pal. Med. Pharm. J.)) the permission to publish the work.

Availability of data and materials

The data and materials are available upon request.

Author's contribution

Khaled Demyati: conceptualization, writing-original draft, data curation, formal analysis, investigation, methodology, project administration, resources, software, supervision, validation, visualization, and writing review & editing. **Alaa Rustom:** conceptualization, writing-original draft, data curation, formal analysis, investigation, methodology, project administration, resources, software, supervision, validation, visualization, and writing review & editing.

Competing interest

None

FUNDING

None

ACKNOWLEDGMENTS

We would like to thank An-Najah University.

REFERENCES

- 1) Abou-Khalil JE, Bertens KA. Embryology, Anatomy, and Imaging of the Biliary Tree. *Surg Clin North Am*. 2019 Apr; 99(2): 163-174. doi: 10.1016/j.suc.2018.12.005. PMID: 30846027.
- 2) Dimitriou I, Katsourakis A, Nikolaidou E, Noussios G. The Main Anatomical Variations of the Pancreatic Duct System: Review of the Literature and Its Importance in Surgical Practice. *J Clin Med Res*. 2018 May;10(5):370-375. doi: 10.14740/jocmr3344w. Epub 2018 Mar 16. PMID: 29581798; PMCID: PMC5862083.
- 3) Katsinelos P, Chatzimavroudis G, Fasoulas K, Katsinelos T, Pilpilidis I, Lazaraki G, Terzoudis S, Kokonis G, Patsis I, Zavos C, Kountouras J. Double major papilla of Vater--a rare endoscopic finding during endoscopic retrograde cholangiopancreatography: a case report. *Cases J*. 2009 Oct 21;2:163. doi: 10.1186/1757-1626-2-163. PMID: 19946474; PMCID: PMC2783119.
- 4) Ratanalert S, Soontrapornchai P. Double orifices of a single major papilla of vater: a rare case report. *Gastroenterol Nurs*. 2007 May-Jun; 30(3): 243-4. doi: 10.1097/01.SGA. 0000278177.07221.bc. PMID: 17568267.
- 5) Kothadia JP, Kone V, Raza A. Double Major Duodenal Papillae: A Rare Congenital Anomaly of Hepatic and Pancreatic Drainage System. *Clin Gastroenterol Hepatol*. 2018 Jul;16(7):A39-A40. doi: 10.1016/j.cgh.2017.09.053. Epub 2018 Feb 6. PMID: 29421157.
- 6) Francis JM, Kadakia SC. Anomalous double orifice of a single major papilla of Vater. *Gastrointest Endosc*. 1994 Jul-Aug;40(4):524-5. doi: 10.1016/s0016-5107(94)70237-3. PMID: 7926559.
- 7) Chavalitdhamrong D, Draganov PV. Unexpected anomaly of the common bile duct and pancreatic duct. *World J Clin Cases*. 2014 Feb 16;2(2):36-8. doi: 10.12998/wjcc.v2.i2.36. PMID: 24579069; PMCID: PMC3936217.
- 8) Mirjalili SA, Stringer MD. The arterial supply of the major duodenal papilla and its relevance to endoscopic sphincterotomy. *Endoscopy*. 2011 Apr;43(4):307-11. doi: 10.1055/s-0030-1256229. Epub 2011 Mar 31. PMID: 21455871.
- 9) Simon MA, Moreira VF, Merono E, Seara JF, del Olmo L. The double papilla of Vater-a reply. *Gastrointest Endosc* 1986;32:120.
- 10) Srdjan P Djuranovic , Milenko B Ugljesic, Nenad S Mijalkovic, Viktorija A Korneti, Nada V Kovacevic, Tamara M Alempijevic, Slaven V Radulovic, Dragan V Tomic, Milan M Spuran. Double common bile duct: a case report. *World J Gastroenterol*. 2007;13(27):3770-3772. doi:10.3748/wjg.v13.i27.3770
- 11) Teilum D. Double common bile duct. Case report and review. *Endoscopy* 1986; 18: 159-161
- 12) Yamashita K, Oka Y, Urakami A, Iwamoto S, Tsunoda T, Eto T. Double common bile duct: a case report and a review of the Japanese literature. *Surgery* 2002; 131: 676-681

- 13) Balan GG, Arya M, Catinean A, Sandru V, Moscalu M, Constantinescu G, Trifan A, Stefanescu G, Sfarti CV. Anatomy of Major Duodenal Papilla Influences ERCP Outcomes and Complication Rates: A Single Center Prospective Study. *J Clin Med*. 2020 May 28;9(6):1637. doi: 10.3390/jcm9061637. PMID: 32481755; PMCID: PMC7356786.
- 14) Phillip V, Schwab M, Haf D, Algül H. Identification of risk factors for post-endoscopic retrograde cholangiopancreatography pancreatitis in a high volume center [published correction appears in PLoS One. 2021 Dec 14; 16(12): e0261576]. *PLoS One*. 2017; 12(5): e0177874. Published 2017 May 17. doi: 10.1371/journal.pone.0177874.