

Knowledge, attitude, and practice regarding deep dentinal caries removal before root canal treatment and restoration among practicing dental surgeons

Sangram Kumar Panda¹, Anamika Sinha¹, Shakti Rath^{2,*} & Kajal Kiran Sahoo¹

¹Department of Prosthodontics and Crown & Bridge, Institute of Dental Sciences, Siksha' O' Anusandhan (Deemed to be) University, ²Central Research Laboratory, Institute of Dental Sciences, Siksha' O' Anusandhan (Deemed to be University), Bhubaneswar, Odisha, India

*Corresponding author: dr.shaktirath@gmail.com

Received: (2/2/2023), Accepted: (24/3/2023), Published: (1/3/2024).

DOI: [0.59049/2790-0231.1109](https://doi.org/10.59049/2790-0231.1109)

ABSTRACT

This article aims to determine the knowledge, attitude, and practice regarding Deep Dentinal Caries Removal before Root Canal Treatment (RCT) and Restoration among practicing dental surgeons. A descriptive cross-sectional study was executed amongst dental surgeons practicing with undergraduate and post-graduate degrees. A Google questionnaire form was developed and distributed, and 111 authentic entries were short-listed. Data obtained from the study were recorded in Microsoft Excel 2007 version, and SPSS version 18.0 was used for statistical analysis. Most dental surgeons who participated in the study practiced for over 15-20 years. Among them, 60% believe in removing dentinal caries before RCT; 83.8% believe in completely removing caries before any restoration, of which only 32.4% use caries-disclosing agents to detect caries. 77.5 % of dentists often encounter cases of RCT failure with incomplete caries removal, and 51.8% believe RCT failure could be due to incomplete caries removal; hence, 83.8% of dentists would recommend complete caries removal to their fellow dentists before RCT. Unnecessary planning of operative tooth intervention makes it go through a lifetime of restorative care through the re-restoration cycle, with additional economic costs with each appointment and an increased chance of premature tooth loss. Diagnostic aids combining visual and tactile examinations, radiographs, and disclosing agents are reliable diagnostic techniques for deciding on any operative intervention for infected dentine. If caries are excavated before any endodontic treatment, a considerable amount of chair time is reduced during crown preparation, and the longevity of the prosthesis is increased.

Keywords: Caries, Disclosing Agents, Caries Detector Dyes, Root Canal Treatment, Restoration.

INTRODUCTION

Dental caries is a multifactorial illness that develops as a result of interactions between the bacterial biofilm (also known as dental plaque), the environment (such as nutrition, salivary composition, flow rate, and fluoride exposure), and the tooth structure [1,2]. The disease process involves changing the ratio of protective factors that help teeth remineralize (i.e., gain minerals back into the tooth). Destructive ones

that help teeth demineralize (i.e., lose minerals from the tooth), which over time leads to demineralization (Figure 1). Oral health practitioners can decide if teeth are suitable candidates for dental sealant implantation by thoroughly understanding the dental caries disease process. The progression of caries disease entails changing the ratio of protective factors that promote tooth remineralization to causative factors that promote tooth demineralization [1,2].

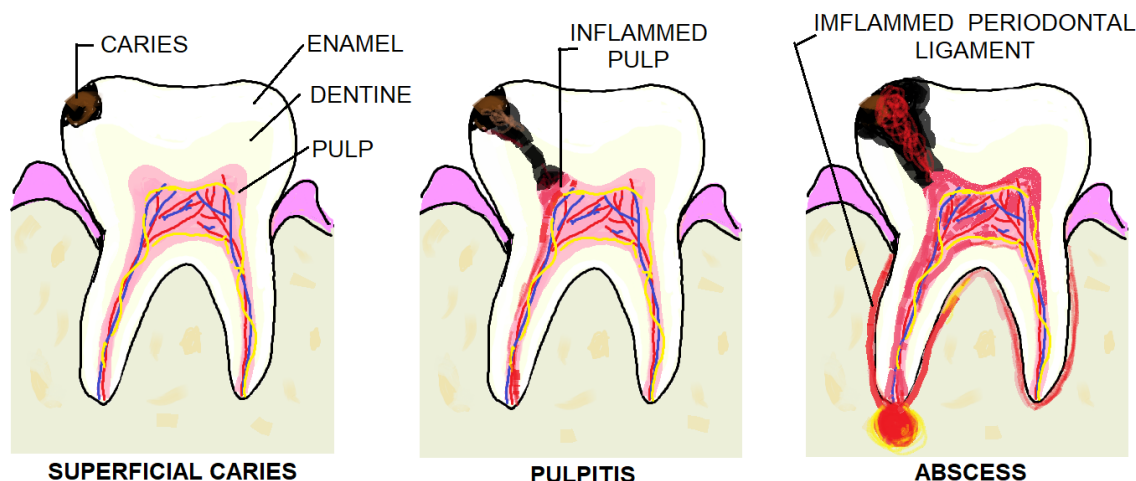


Figure (1:) Process and progress of dental caries.

Any dental surgeon's main goal is to altogether remove carious tissue, including the entire biomass of irreversibly demineralized enamel and dentinal tissue. If the tooth has carious tissue, any new restoration or prosthesis will have difficulty adhering to this heavily infected dentine tissue. Consequently, the final restoration's long-term prognosis is negatively impacted. The progression of the lesion can be halted by simply removing the biofilm or by sealing the bacteria within the cavity and restoring the tooth to allow for regular removal of the biofilm. Tomes believes discolored dentine should be left to protect the pulp rather than risk sacrificing the tooth. Still, in 1908 [3], Black disagreed, claiming the tooth should be removed from all decayed dentine overlaying [4].

The only physical criterion dentists use as a guide for clinical excavation of this infected demineralized dentin is the tissue's hardness or texture. However, some dentists also place importance on the colour of the tissue and may use caries detector dyes. However, in clinical practice, all these criteria differ from dentist to dentist, resulting in variations in the quality and quantity of dentin removed during the operative intervention. The composite restorations placed over soft carious tissue (the infected dentine) showed a higher rate of clinical failures than amalgam restorations placed over teeth in which complete excavation of caries has been done [5]. Some restorations were placed over a residual layer of soft dentine fractured after 36-45 months [6]. If a layer of carious dentine is left beneath a restoration,

its strength is influenced by restoration in two ways. Firstly, higher bond strengths are achieved when restoration material is bonded to sound instead of carious dentine [7-9]. Secondly, carious dentine is softer and has a lower Young's modulus than sound dentine [10,11]. Both factors might result in the degradation of the tooth-restoration complex, leading to increased marginal stresses and susceptibility to fatigue failure. Therefore, when carious tissue is left beneath the restoration, the fracture strength of the tooth-restoration complex is reduced [12].

Dentists often need help during crown preparation of endodontically treated teeth in which caries have not been removed. Therefore, it becomes imperative for the practitioner to restore before proceeding with the crown preparation, which again increases the chair-side time and lengthens the appointment, which busy practitioners look down upon. Hence, dentists often recommend complete caries removal before starting with endodontic treatment and restoration. In this questionnaire, we have tried to emphasize the importance of caries removal before proceeding with any endodontic treatment and also the longevity of the restorations and prostheses.

Aims And Objectives

To determine the knowledge, attitude, and practice regarding Deep Dentinal Caries Removal before Root Canal Treatment and Restoration amongst practicing dental surgeons.

METHODS

A descriptive cross-sectional study was executed amongst dental surgeons practicing with undergraduate and post-graduate degrees who practice endodontic Treatment in their clinic or institution. A 20-module questionnaire form was prepared by revising available literature and previously published scientific research studies, articles, and guidelines. Information from the retrieved data was pooled, and the invigilator framed the questionnaire. The prepared questions were revised, pilot-tested, and finally minimized to 15 questions. A Google questionnaire form was prepared with the final short-listed 15 questions for easy access to the dental practitioner due to the ongoing pandemic. The documents were distributed, and 111 validated entries were obtained.

The inclusion criteria were all the practicing dental surgeons who practice the Treatment of conservative restoration of teeth, endodontic therapy, and subsequent prosthesis in their set-up/ clinic/ hospital. In the exclusion criteria, any non-practicing dental surgeons or other dental surgeons who don't practice the conservative restoration of teeth, endodontic therapy, and subsequent prosthesis in their set-up/ clinic/ hospital. Data obtained from the study were recorded in Microsoft Excel 2007 version, and SPSS version 18.0 was used. All the categorical factor representation was done in numbers and percentages. Calculation of

statistical analysis like mean and standard deviation and analysis between variations was done using student t-tests, and the association between variables was determined using Chi-square. A value was found significant when the p-value was less than 0.05. Ethical approval or consent was not required because it is a KAP study and has no involvement of patients, biological samples, or animals. The authors ensure they have followed the Helsinki Declaration guidelines and maintained the participants' privacy in the study.

RESULTS

The study included 111 dental surgeons, of which the majority have more than fifteen years of experience in their respective fields. Out of 111 responses received, 88.3% perform root canal treatment in their clinic/set-up/ hospital. Among these, 60% have felt the need to remove deep dentinal caries before proceeding with RCT. And 83.8% believe in completely removing caries before proceeding with any restoration. 32.4% use caries-disclosing agents. Among these, 77.5% encounter cases of RCT failure with incomplete caries removal. Among 111 dentists, 73% face difficulty in tooth preparation for the crown in an improperly excavated endodontically treated tooth. 83.8% recommend complete caries removal to your fellow dentist before proceeding with RCT. The results of all the questionnaires are documented in Table 1.

Table (1): Details of responses to the questionnaires.

Question	Total Number of Responses	Details of Responses		
Root canal treatment in clinic/setup/hospital	111	Yes (88.3%)	No (11.7%)	--
Need of removal of deep caries proceeding with RCT	111	Every time (60%)	Sometimes (37.3%)	Maybe (2.7%)
Believe in the complete removal of caries before proceeding with any restoration	111	Yes (83.8%)	No (2.7%)	Not Sure (13.5%)
Usage of caries-disclosing agents to detect caries	111	Yes (42.3%)	No (25.2%)	Not Sure (42.3%)
Encounter cases with RCT failure with incomplete caries removal	111	Sometimes (10.8%)	Always (11.7%)	Never (77.5%)
RCT failures are mostly due to incomplete caries excavation before proceeding with RCT	111	Agree (51.8%)	Disagree (15.5%)	Not Sure (32.7%)

Question	Total Number of Responses	Details of Responses		
Recommend complete caries removal to your fellow dentist before proceeding with RCT	111	Yes (83.8%)	No (3.6%)	Maybe (12.8%)
Face difficulty in tooth preparation for the crown in an improperly excavated endodontically treated tooth	111	Yes (73%)	No (6.3%)	Sometimes (20.7%)
Restoration of the carious part after caries removal before proceeding with tooth preparation for crown	111	Yes (71.2%)	No (7.2%)	Sometimes (21.6%)
Recommend complete caries removal before restoration to your fellow dentists	111	Yes (95.5%)	No (4.5%)	--

DISCUSSION

The treatment plan for any carious teeth requiring operative intervention should be complete removal of infected dentin, followed by placement of a restoration, which should be well sealed and long-lasting. Improper caries removal leads dentists to spend more time re-treating the restored teeth than treating primary decay. This re-restoration cycle considerably weakens teeth, and the lesion consequently involves the pulp. Incomplete removal also decreases structural strength in the case of any endodontically treated tooth [13-15].

In the survey, 83.8 % of the dental surgeons believed in completely removing caries before proceeding with any restoration, and 60% of dentists felt the need to remove deep dentinal caries before proceeding with RCT. Diagnostic methods like tactile and visual criteria are normally used to detect a carious lesion, as found in our survey in which 47.7% of dentists prefer radiographs, 36% prefer visual-tactile, and 10.8% prefer only visual examination. Any diagnostic tool that would help differentiate healthy dentin from carious ones is considered useful, as our survey found that 32.4 % of dental surgeons use caries detection dyes for diagnosing carious teeth.

Techniques that help preserve tooth structure should be taken from the initial step of a treatment plan for managing severe caries. For example, if proximal caries is evident on radiographs in enamel only, it is invariably non-cavitated. Still, it should be treated and arrest its progression towards dentin, which will, in

turn, help in conserving tooth structure [17-19]. In the survey, 44.1% of the dentists prefer caries removal with an air rotor with a diamond point, 26.1% with a Spoon excavator, and 23.4% with an Air rotor with a carbide bur. Endodontic Treatment is the classical Treatment for deep carious lesions encroaching pulp. A common factor that can be easily attributed to any endodontic failure is the presence of bacteria from caries, which have not been excavated and can be present in both intracanal and extra canals. In our survey, 51.8 % of the dentists agree that RCT failures are primarily due to incomplete caries excavation before proceeding with RCT [17-19]. A similar study was conducted in 2018 in India, which looked for outcomes of Partial and complete caries excavation in Permanent Teeth after an 18-month follow-up. They found a better success rate in complete caries removal [20].

Thus, 83.8% of the dentists who participated in our study recommend complete caries removal to their fellow dentists before proceeding with RCT. According to studies, it has been found that if restoration is done after complete excavation of caries, the teeth tend to have lower fracture strength than in teeth in which restoration is done after complete excavation. Also, in our survey, 73% of dentists need help in tooth preparation for the crown in an improperly excavated endodontically treated tooth. In contrast, instrumentation, the tooth structure being brittle, tends to chip off. Hence, 71.2 % of the dentists in our survey restore the carious part before proceeding with tooth preparation for the required crown.

Among all the dentists in our survey, 56.8% prefer composite for restoring the carious infected region of the tooth, and 32.4% prefer GIC. [21-24].

The significance of this questionnaire study lies in the fact that it will act as an eye opener to the presently practicing fellow dental surgeons who deliberately practice endodontic Treatment and subsequent prosthesis delivery and yet fail to decipher the reason for their continuous treatment failure. In this study, we have gathered how a simple carious lesion can turn into a long-term headache for both the patient and the treating dentist due to incomplete dentinal caries removal, leading to subsequent restoration failure or failure of endodontic therapy or prosthesis failure. Therefore, this study encourages us to use various carious detection methods, including physical, visual, and radiographic methods, to rule out caries before proceeding with any other subsequent treatment.

CONCLUSION

Procedures used to diagnose caries must be specific, valid, reliable, and clinically proven. Caries-detector does help in the differentiation between healthy and diseased tooth structures, which helps the clinician identify caries. At the same time, specific guidelines should be implemented while dealing with endodontically treated teeth, which will help in ensuring the longevity of the restoration and prosthesis.

FUNDING: None.

Ethical issues: No ethical issues.

Conflicts of interests: No conflicts of interests.

Author's contribution

SP and **SR** conceptualized, analyzed the data, interpreted the results and finalized the manuscripts. editing. **AS** and **KKS** conducted the study, collected the data and drafted the original manuscript.

REFERENCES

- 1] Selwitz RH, Ismail AI, Pitts NB. Dental caries. *Lancet*. 2007;369(9555):51-59.
- 2] Rath S, Bal SCB, Dubey D. Oral Biofilm: Development Mechanism, Multidrug Resistance, and Their Effective Management with Novel Techniques. *Rambam Maimonides Med. J* 2021;12(1): e0004.
- 3] J. Tomes, A System of Dental Surgery, John Churchill, London, UK, 1st edition, 1859.
- 4] Black GV. A Work on Operative Dentistry. Volume 2: The Technical Procedures in Filling Teeth. Chicago: Medico-Dental Publishing Company; 190
- 5] Mertz-Fairhurst EJ, Curtis JW, Ergle JW, Rueggeberg FA, Adair SM. Ultraconservative and cariostatic sealed restorations: results at year J Am Dent Assoc. 1998; 129:55-66.
- 6] Maltz M, Oliveira EF, Fontanella V, Carminatti G. Deep caries lesions after incomplete dentine caries removal: a 40-month follow-up study. *Caries Res*. 2007; 41:493-496
- 7] Xie J, Flaitz CM, Hicks MJ, Powers JM. Bond strength of composite to sound and artificial carious dentin. *Am J Dent*. 1996; 9:31-33.
- 8] Yoshiyama M, Tay FR, Doi J, Nishitani Y, Yamada T, Itou K, et al. Bonding of self-etch and total-etch adhesives to carious dentin. *J Dent Res*. 2002; 81:556-560
- 9] Say EC, Nakajima M, Senawongse P, Soyman M, Özer F, Tagami J. Bonding to sound vs caries-affected dentin using photo- and dual-cure adhesives. *Oper Dent*. 2005; 30:90-98.
- 10] Marshall GW, Habelitz S, Gallagher R, Balooch M, Balooch G, Marshall SJ. Nanomechanical properties of hydrated carious human dentin. *J Dent Res*. 2001; 80:1768-1771.
- 11] Zheng L, Hilton JF, Habelitz S, Marshall GW. Dentin caries activity status is related to hardness and elasticity. *Eur J Oral Sci*. 2003; 111:243-252.
- 12] Unlu N, Ermis RB, Sener S, Kucukyilmaz E, Cetin AR. An in vitro comparison of different diagnostic methods in the detection of residual dentinal caries. *Int J Dent*. 2010; 2010:864935.
- 13] Thompson V, Craig RG, Curro FA, Green WS, Ship JA. Treatment of deep carious

- lesions by complete excavation or partial removal: a critical review. *J Am Dent Assoc.* 2008;139(6):705-712.
- 14] McComb D. Caries-detector dyes--how accurate and useful are they? *J Can Dent Assoc.* 2000;66(4):195-198.
 - 15] Kobayashi M, Inagaki R, Ichikawa K, et al. Effect of kinematic viscosity on the staining performance of caries detector dyes. *Dent Mater J.* 2019;38(1):120-126.
 - 16] Yildiz E, Sirinkaraarslan E, Yegin Z, Cebe MA, Tosun G. Effect of caries removal techniques on the bond strength of adhesives to caries-affected primary dentin in vitro. *Eur J Paediatr Dent.* 2013;14(3):209-214.
 - 17] Braga MM, Chiarotti APS, Imparato JCP, Mendes FM- Validity and reliability of methods for the detection of secondary caries around amalgam restorations in primary teeth. *Braz Oral Res.* 2010;24(1):102-7
 - 18] Datta D, Ramesh SG, Narayanan M, Selvamary LA, Sujatha A. Disclosing solutions used in dentistry, *World J Pharm Res.* 2017; 6(6):1648-1656
 - 19] Hevinga MA, Opdam NJ, Frencken JE, Truin GJ, Huysmans MC. Does incomplete caries removal reduce the strength of restored teeth? *J Dent Res.* 2010;89(11):1270-1275.
 - 20] Khokhar M, Tewari S. Outcomes of partial and complete caries excavation in permanent teeth: A 18-month clinical study. *Contem Clini Dentistry.* 2018;9(3):468.
 - 21] Javaheri M, Maleki-Kambakhsh S, Etemad-Moghadam Sh. Efficacy of two caries detector dyes in the diagnosis of dental caries. *J Dent (Tehran).* 2010;7(2):71-76.
 - 22] Javaheri M, Kambakhsh M, Etemad-Moghadam. Effect of an alcohol-based caries detector on the surface tension of sodium hypochlorite preparations. *Brazilian Dental J.* 2015; 26(1): 66-68
 - 23] Van Hilsen Z and Jones R, HilsenV. Comparing potential early caries assessment methods for teledentistry. *BMC Oral Health.* 2013; 13:16
 - 24] Zaidi I, Somani R, Jaidka S, Nishad M, Singh S, Tomar D-Evaluation of different Diagnostic Modalities for diagnosis of Dental Caries: An in vivo Study. *Int J Clin Pediatr Dent.* 2016;9(4):320-325.