

Metformin-Associated Lactic Acidosis Successfully Treated with Hemodialysis: A Case Report

Mo'tasem Dweekat¹; Dina Abugaber¹; Ali Shakhshir²; Yousef El Hamshary^{1,*}

¹Department of internal medicine, An-Najah National University Hospital, An-Najah National University, Nablus, Palestine. ²Department of medicine, An-Najah National University, Nablus, Palestine

*Corresponding author: yousef.hamshari@gmail.com

Received: (7/6/2023), Accepted: (3/5/2024), Published: (1/12/2024). DOI:

<https://doi.org/10.59049/2790-0231.1150>

Abstract

Metformin, a commonly used biguanide antihyperglycemic agent, has a well-documented association with lactic acidosis. Most reported cases of metformin-related lactic acidosis were due to medication overdose or preexisting liver or kidney disease. In this case, a 62-year-old female with Type II diabetes mellitus, hypertension, and ischemic heart disease presented with decreased mentation, lactic acidosis, and acute kidney injury. Our patient had no history of kidney or liver disease. The patient developed the complication due to a therapeutic dose. Intravenous sodium bicarbonate was her initial treatment. As her condition did not improve, she underwent one session of hemodialysis, following which she dramatically improved. Eventually, we discharged the patient to her baseline status. In our experience, hemodialysis was very effective in managing metformin-associated lactic acidosis. We report this case to raise clinicians' awareness of this complication and to encourage hemodialysis as an early management option.

Keywords: Metformin, Hemodialysis, Case report, Acidosis.

INTRODUCTION

Metformin is a commonly used medication in the treatment of Type II diabetes mellitus (TIIDM) as well as to help prevent or delay the development of the disease for those at risk [1]. Many societies and associations around the world choose metformin as the drug of choice for the initial management of TIIDM [2]. It is a biguanide antihyperglycemic agent and is usually well tolerated [3]. Additionally, metformin has been shown to have mortality benefits as well as reduce cardiovascular events in diabetic patients [4].

Common adverse effects include diarrhea, nausea, and abdominal pain [5]. Though it is associated with lactic acidosis, the incidence is rare, at 6.3 per 100,000 patient-years [6]. This complication carries a mortality rate reported between 8% and 50% [4]. Most reports of metformin-associated lactic acidosis describe patients with preexisting comorbidities such as liver disease, advanced age, alcoholism, renal disease, or cardiopulmonary disease, which in and of themselves can cause metformin accumulation or lactic acidosis [4]. Others

describe metformin overdoses, whether intentional or accidental [7].

Treatment options for lactic acidosis due to any cause revolve around reversing the initial cause of lactic acidosis. Supportive measures like intravenous sodium bicarbonate and intravenous fluid resuscitation are other treatment options [8]. Metformin has no antidote but is a dialyzable medication. Fortunately, hemodialysis is a treatment option for both metformin toxicity and its complications, lactic acidosis. Most reported cases of successfully treated metformin-associated lactic acidosis mention significant improvement following hemodialysis, whether intermittent or continuous [7].

In our case report, we present a 62-year-old female patient without known liver or renal disease who presented to our hospital with decreased mentation and an undetectable low pH.

Case Presentation

The patient was a 62-year-old middle eastern female known to have Type II diabetes mellitus, hypertension, ischemic heart disease, cerebrovascular disease, and peripheral

vascular disease. She uses insulin glargine and insulin aspart to control her blood sugar. However, an outpatient doctor evaluated her at his clinic and prescribed once daily oral metformin 850 milligrams (mg) for better control of her diabetes. Two days later, coincidentally, she started to complain of symptoms consistent with a urinary tract infection (UTI). Moreover, she mentioned a history of decreased oral intake and vomiting twice. A few days later, she was treated with levofloxacin 750 mg once daily. Following that, she started to complain of abdominal pain and myalgia, which was treated at home with intramuscular diclofenac sodium 75 mg and dexamethasone 4 mg. Her condition deteriorated as she developed confusion and lethargy, necessitating a transfer to a hospital. She reported taking all of her home medications, including atorvastatin 40 mg daily, valsartan 160 mg daily, hydrochlorothiazide 12.5 mg daily, insulin glargine and insulin aspart, along with metformin 850 mg during her illness without vomiting following medication ingestion.

On presentation to our hospital, An Najah National University Hospital in Nablus-Palestine, she was confused and drowsy but conscious and responsive; her Glasgow Coma Scale score was 14/15 (E4V4M6). She had obvious rapid, deep breathing with no desaturation. Initially, her blood pressure reading was 120/60 mmHg, and her heart rate was 85 beats per minute (BPM). Her mucus membranes were dry, and her capillary refill was delayed, but her heart, chest, and abdomen examinations were unremarkable.

Her initial arterial blood gases (ABGs) showed unrecordably low pH and bicarbonate levels. Her initial lactate level was 16 mmol/L, and her random blood sugar was 159 mg/dL. She was treated with 100 milliequivalents of sodium bicarbonate along with Ringer lactate boluses and transferred to the medical intensive care unit (MICU). Following her admission to the MICU, she became severely hypotensive at 70/30 mmHg and required a high-dose infusion of noradrenaline and vasopressin due to hemodynamic instability. Repeated ABGs

showed a pH of 6.88, a bicarbonate of 4.8 mmol/L, a lactate of 26 mmol/L, and an anion gap of 51. Her initial investigations revealed a creatinine level of 6.8 mg/dL and a potassium level of 5.5 mmol/L. The differential diagnosis was metformin-associated lactic acidosis, mesenteric ischemia, and diabetic ketoacidosis (DKA). Diabetic ketoacidosis was unlikely considering her normal blood sugar and the absence of risk factors for euglycemic DKA. A computed tomography scan of the abdomen was conducted prior to ICU admission and showed no signs consistent with mesenteric ischemia. No contrast was used due to deranged kidney function. Therefore, our admitting diagnosis was metformin-associated lactic acidosis, as it had started recently with an acute deterioration of her kidney function, which raised the risk of developing metformin toxicity.

The patient was started on a sodium bicarbonate infusion along with aggressive intravenous (IV) fluid resuscitation. Despite all efforts, her follow-up blood gases remained largely unchanged, and the patient underwent a session of hemodialysis (HD) with a bicarbonate of 40 mmol/L for 3 hours with low flow of blood and dialysate, due to her severe hemodynamic instability, and no ultrafiltration. During hemodialysis, adrenaline was needed as a third-line vasopressor. Following hemodialysis, her consciousness improved to GCS 15/15, pH to 7.30, bicarbonate to 12.9 mmol/L, and lactate to 19 mmol/L. Supportive management, mainly in the form of IV fluid resuscitation was continued, and the patient's urine output gradually improved to greater than 0.5 mL/kg. Over the following 24 hours, her vasopressor requirements decreased, and by 48 hours, vasopressors were discontinued. Her lactate level normalized 72 hours after the hemodialysis session, and she was transferred to the medical ward. She was discharged home 4 days after presentation with a down-trending creatinine of 1 mg/dL and a normal lactate level. (Table 1) illustrates her arterial blood gas (ABG) readings over the course of hospitalization.

Table (1): Arterial blood gases (ABG) over the course of hospitalization.

	Presentation	1 Hour	Post Hemodialysis	2 Days Later	Reference Range
pH	Unrecordable Low	6.88	7.30	7.50	7.35–7.45
pCO ₂ (mmHg)	14	12	20	26	75–100
Bicarbonate (mmol/L)	Unrecordable Low	4.8	12	23	22–26
Lactate (mmol/L)	18	26	19	1	0.5–2.2

Table (1): pCO₂; partial pressure of CO₂, mmHg; millimeter mercury, mmol; millimole, L; liter

DISCUSSION

Metformin is a favorite antidiabetic to many clinicians around the globe, given that it is recommended by many societies as the first line of management for T1DM and for its favorable side effect profile. It has also been shown to reduce mortality and cardiovascular events in diabetic patients [4].

Based on the chronology of events with our patient, we believe she developed prerenal azotemia due to decreased oral intake and active fluid loss due to vomiting, which led to hypovolemia. Hypovolemia, urinary tract infection (UTI), the Non-steroidal anti-inflammatory drug (NSAID) diclofenac sodium, and the angiotensin receptor blocker valsartan likely contributed to her kidney injury. This coincided with the introduction of metformin to her medication regimen.

Renal impairment raises metformin blood levels due to decreased clearance [9]. Metformin decreases lactate metabolism by suppressing pyruvate carboxylase, which is the likely mechanism by which metformin-associated lactic acidosis develops. It is also thought to decrease glucose utilization and increase lactate production in hepatocytes [10].

Irrespective of the etiology, lactic acidosis causes a reduction in cardiac contractility and an increased risk of cardiac arrhythmias, both of which are precipitators of cardiac arrest. It is also associated with increased mortality, irrespective of organ failure or shock [8]. However, lactic acidosis due to metformin accumulation has been shown to have a better outcome than lactic acidosis due to other etiologies [11].

Measurement of the metformin level is extremely helpful in confirming the diagnosis of metformin toxicity and, thus, in its management. The therapeutic level for metformin is usually less than 2 µg/mL. When metformin is implicated in lactic acidosis, its drug levels are usually >5 µg/mL [9]. Unfortunately, metformin level is not available in our hospital, like in many others.

When metformin toxicity is due to an overdose, gastrointestinal decontamination is the first step in management using activated charcoal [10]. However, our patient was using a regular dose of the drug, with the last dose taken well out of the window for gastrointestinal decontamination.

The Extracorporeal Treatments in Poisoning (EXTRIP) Workgroup recommends intermittent hemodialysis (HD) for the treatment of metformin-associated lactic acidosis. When HD is not available, they recommend consideration for continuous renal replacement therapies. In severe cases where the lactate concentration is greater than 15 mmol/L and the pH is lower than 7.0, associated with shock or organ dysfunction, dialysis is recommended [12]. Our patient was in shock with a pH <7.0, lactate >15 mmol/L, and no significant improvement on the sodium bicarbonate infusion. (Figure 1) clearly shows the dramatic change in the patient's bicarbonate and lactate levels following one 3-hour session of HD. As far as we know, this is the first case to be reported in Palestine with metformin-associated lactic acidosis without a previous history of kidney or liver disease and no overdose. Only two previous case reports had similar scenarios, one from England [13] and one from the United States [14]. In both

cases, acute kidney injury was complicated by lactic acidosis, with a therapeutic dose of metformin being the culprit. Both cases, like

ours, were successfully treated with renal replacement therapy.

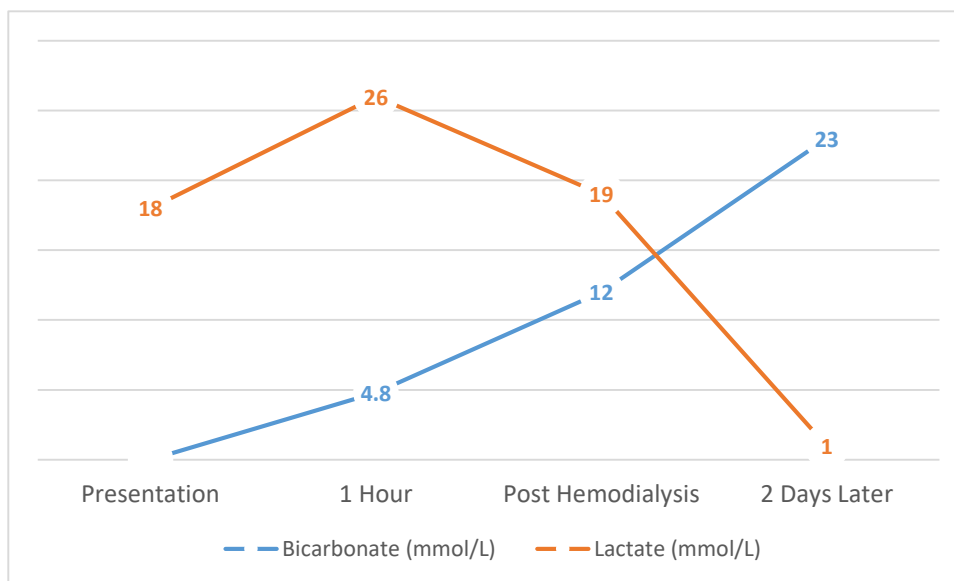


Figure (1): Bicarbonate and Lactate levels over time.

Figure (1): mmol; millimole, L; liter

CONCLUSION

Most reported cases of metformin-associated lactic acidosis are either due to preexisting kidney or liver disease or drug overdose. Our patient developed this complication while taking a therapeutic dose of the medication. In our experience, hemodialysis was very effective in managing metformin-associated lactic acidosis. Our patient experienced dramatic improvement in both clinical and laboratory measures following hemodialysis. We report this case to raise awareness among clinicians about the need to consider this complication when faced with lactic acidosis and to consider hemodialysis early on when dealing with patients suspected of having it.

Ethics approval and consent to participate

An Najah National University and An Najah National University Hospital (NNUH) protocol do not require an ethical approval to publish case reports.

Consent for publication

Verbal consent was obtained from the patient to publish this case report.

Availability of data and materials

All involved data was extracted from NNUH electronic health care system.

Author's contribution

Mo'tasem Dweekat: Writing and editing the original manuscript draft. **Dina Abugaber:** Conceptualization, project administration, validation and supervision. **Ali Shakhshir:** Writing and reviewing the final draft of the manuscript. **Yousef El Hamshary:** Conceptualization, project administration, validation and supervision

Competing interests

The authors declare that there are no competing interests in this project.

Funding

No funding was needed for this project

Acknowledgments

The authors really appreciate the kind acceptance of the patient to publish his case in order to nourish literature with valuable medical information that could be an insight for future effective management.

REFERENCES

- 1] Aroda VR, Ratner RE. Metformin and

- type 2 diabetes prevention. *Diabetes Spectr.* 2018;31(4):336–42.
- 2] Inzucchi SE, Lipska KJ, Mayo H, Bailey CJ, McGuire DK. Metformin in patients with type 2 diabetes and kidney disease: a systematic review. *Jama.* 2014;312(24):2668–75.
- 3] Maruthur NM, Tseng E, Hutfless S, Wilson LM, Suarez-Cuervo C, Berger Z, et al. Diabetes medications as monotherapy or metformin-based combination therapy for type 2 diabetes: a systematic review and meta-analysis. *Ann Intern Med.* 2016;164(11):740–51.
- 4] Sr S, Ga P. Risk of fatal and nonfatal lactic acidosis with metformin use in type 2 diabetes mellitus (Review). 2010;
- 5] Triggie CR, Ding H. Metformin is not just an antihyperglycaemic drug but also has protective effects on the vascular endothelium. *Acta Physiol.* 2017;219(1):138–51.
- 6] Salpeter SR, Greyber E, Pasternak GA, Salpeter EE. Risk of fatal and nonfatal lactic acidosis with metformin use in type 2 diabetes mellitus: systematic review and meta-analysis. *Arch Intern Med.* 2003;163(21):2594–602.
- 7] Leonaviciute D, Madsen B, Schmedes A, Buus NH, Rasmussen BS. Case Report Severe Metformin Poisoning Successfully Treated with Simultaneous Venovenous Hemofiltration and Prolonged Intermittent Hemodialysis. 2018;2018.
- 8] Foucher CD, Tubben RE. Lactic acidosis. In: *StatPearls* [Internet]. StatPearls Publishing; 2023.
- 9] Defronzo R, Fleming GA, Chen K, Bicsak TA. Metformin-associated lactic acidosis: Current perspectives on causes and risk. *Metabolism* [Internet]. 2015;65(2):20–9. Available from: <http://dx.doi.org/10.1016/j.metabol.2015.10.014>
- 10] Kopec KT, Kowalski MJ. Metformin-associated lactic acidosis (MALA): case files of the Einstein Medical Center medical toxicology fellowship. *J Med Toxicol.* 2013;9:61–6.
- 11] Friesecke S, Abel P, Roser M, Felix SB, Runge S. Outcome of severe lactic acidosis associated with metformin accumulation. *Crit Care.* 2010;14(6):1–5.
- 12] Calello DP, Liu KD, Wiegand TJ, Roberts DM, Laverne V, Gosselin S, et al. Extracorporeal treatment for metformin poisoning: systematic review and recommendations from the extracorporeal treatments in poisoning workgroup. *Crit Care Med.* 2015;43(8):1716–30.
- 13] Fitzgerald E, Mathieu S, Ball A. Metformin associated lactic acidosis. *Bmj.* 2009;339.
- 14] Santoli J, Aldakkour JL, Tohidi H, Lin Y. Case Report Metformin-Associated Lactic Acidosis: A Case Report. 2023;215–8.