

Alleviating Bisphenol-A Induced Renal Toxicity: Protective Efficacy Garlic Extract in A Mammalian Model by Biomarker Analysis

Faheem Nawaz^{1,*}, Chaman Ara¹, Asmat Ullah¹, Sana Akbar¹, Madeeha Mehboob¹ & Naveed Akhtar²

Received: 15th May, 2024, Accepted: 6th Jul, 2024, Published: xxxx, DOI: <https://doi.org/xx.xxxx>

Accepted Manuscript, In press

ABSTRACT: Background: The present study was conducted to assess the adverse effects of Bisphenol-A (BPA) on renal functions and to evaluate the potential mitigating impacts of fresh garlic extract. **Methodology:** A total of 50 albino mice were housed in control conditions within the animal house. These animals were orally administrated BPA and fresh garlic extract for duration of 28 days. Subsequently, the mice were categorized into five groups: Control (G-I), Vehicle control (G-II), BPA treated (G-III), Antidote treated (G-IV) and Fresh garlic extract treated (G-V), each consisting of 10 individuals (n=10). Following the 28-day exposure period, all mice were humanely euthanized, and their kidneys were subjective to comprehensive analysis to diagnose the effects of both BPA and fresh garlic extract. **Results:** Renal function tests were conducted to find the toxicological implications of BPA, while Ferric Reducing Antioxidant Power (FRAP) and Total Phenolic Contents (TPC) assays were used to evaluate the potential ameliorative effect of fresh garlic extract. Additionally, his to-pathological assessments performed to scrutinize the structure integrity of the kidneys. This research revealed that BPA-induced toxicity, resulting in alleviation level of urea and creatinine. Conversely mice treated with fresh garlic extract exhibited divergent response. Notably the fresh garlic extract effectively mitigated the effect of BPA leading to a restoration of normal kidney structure and functionally. **Conclusions:** The current findings under-score, the potential therapeutic utility of fresh garlic extract in ameliorating BPA-induced renal toxicity.

Keyword: Albino Mice, Fresh Garlic Extract, Ferric Reducing Antioxidant Power, Total Phenolic Content, Histopathological.

INTRODUCTION

The garlic (*Allium sativum*, Liliaceae) is a widely utilized spice and medicinal herb, found not only in Central Asia and north-eastern Iran but also across the globe. It boasts a diverse array of chemical compounds including allicin, alliin, S-allyl cysteines, thiaceomonone, diallyl-disulfide, and diallyl sulphide, all of which are found in abundant quantities. This botanical and its constituents offer a range of advantages encompassing free radical scavenging, anti-inflammatory anti-cholesterolemic, anti-gastric ulcer, anti-microbial, anti-cancer and antioxidant properties [27, 10, 34]. It has been substantiated in numerous studies for its prominent impact on cardiovascular risk factors such as dyslipidemia, high blood pressures and blood sugar levels. Furthermore, it enhances fibrinolytic activity inhibits platelet aggressions and exert antioxidant effects. Additionally, allium family demonstrates protective effects during pregnancy, potential attributed to the inhibition of lipid synthesis-related enzymes, prevention of lipid peroxidation, and reduction of LDL oxidation through superoxide scavenging and elevation of antioxidant levels [7,

2]. BPA a primary component of epoxy resins used in lining of food and beverages containers and in polycarbonate, plastic for food and beverage storage is widely produced. Research has demonstrated that BPA can leach-out from these products while using them, indicating constant threat. Given its widespread use in various daily items. Given its widespread use in everyday items, It is not surprising that BPA have been detected in most individuals tested. Extensive studies on laboratories animals have highlighted the detrimental effects of BPA on reproductive, neurological and metabolic functions [11, 16]. More-over exposure to high intensity of BPA through the skin has been demonstrated to substantially impact human's kidney, livers, reproductive systems and other vital organs [22]. Multiple investigations have been documented oxidative damage in rodents exposed to BPA [19, 30, 6]. This includes BPA induced damage in the tissues of brain, kidney, liver and other organs by generating reactive oxygen species (ROS) [9, 26]. Thereby elevating lipid peroxidation and diminishing the activity of antioxidant enzymes, ultimately leading to oxidative stress [29, 4, 14].

¹ Developmental Biology Lab, Institute of Zoology, University of the Punjab, Quaid-e-Azam Campus, Lahore, Pakistan.

*Corresponding author's email: faheem263@gmail.com

² Department of Zoology, Govt. College University, Lahore. Pakistan.

Main objective of the current study garlic extract is harnessed as a natural antioxidant against BPA and use renal toxicity while a multitude of medications are utilized globally to mitigate BPA toxicity, they frequently exhibit lower efficacy in recovery and may be associated with health effects.

MATERIAL METHODS

Chemicals: The chemicals utilized in this study adhere to international standards BPA was sourced from reputable supplier namely Duskan (USA) and Sigma Aldrich (Australia). Additionally, ethanol, formic acid and methanol were used to extract polyphenols. The antioxidant assay employed Sodium Carbonate, Sodium Acetate, Gallic Acid, Aluminium Chloride, Sulphuric acid Ascorbic acid, 2, 4, 6-tripyridyl-s-triazine (TPTZ), Gallic acid and ferric acid.

Animal husbandry: Fifty adult male albino mice were obtained from the esteemed university of veterinary and animal sciences UVAS Lahore Pakistan. Upon procurement, they were transported to the Institute of Zoology, University of the Punjab, Lahore, where they were acclimatized under standard conditions. The mice were maintained on a 12-hourslight/dark cycle at a temperature of 25° C. All the procedures were adhered to the NIH publication "Guide for Care and Use of Laboratory Animals" (NRC 2004) and followed the guidelines set by the University's local bioethical committee on animal experimentation [25].

Experimental design: To acclimatize all 50 mice maintain under native conditions before the commencement of experiment. Subsequently, they were orally administrative fresh garlic extract and BPA via gavage for duration of 28 days. Post-injections, the mice were randomly divided into five groups, each consisting of 10 mice. These groups were desired designated as G-I (control) G-II (vehicle control), G-III (1200mg/kg of body weight, BPA treated) G-IV (Antidote) and G-V (fresh garlic extract). The treatment of all animals started simultaneously [17]. Experimental equipment and apparatus were manufactured from metals and glassware to avoid potential of environmental interference.

Garlic extract preparation

1. Garlic Clove and distill water: garlic clove are the individual segments found within the bulb of garlic. These garlic cloves and distill water were main component.
2. Ratio measurement: precisely 30 grams of garlic cloves were taken and 100mL distil water were utilized. This was done to ensure the consistency and accuracy in the concentration of the extract.
3. Homogenization: The garlic cloves are then homogenized in 100mL of distil water. This include the blending of garlic clove thoroughly with the water to create a uniform mixture. This was achieved by an electric blender (Blender NB-4020, National).
4. Filtration: After well-homogenized blende, the mixture was filtered three time. a) The first filtration was typically done using cheesecloth to remove large particle. b) The second filtration was done by using filter paper to remove smaller particle. c) Ensure that the resulting liquid is pure, likely using a very fine filter i.e., micro-filter,
5. Centrifugation: The resulting filtered liquid subjected to centrifugation, which showed the final concentration of the garlic extract is 500mg/mL. This concentration was derived from the final initial 30grams of garlic clove (30,000mg/100mL). Since the entire process, no significant volume lost during the preparation.
6. Daily fresh extract preparation: The extract was prepared fresh every day through-out the experiment. This enables

the extract remained potent and effective, as some of the active compounds in garlic can degraded over time.

Biochemical Testing: Anesthetized mice provided blood samples, were collected in vials and sent to the laboratory for necessary testing, 24 hours after the final dosage. Subsequently, the mice were euthanized for the collection of vital organs for further analysis.

Ferric Reducing Antioxidant Potential (FRAP): The FRAP assay was conducted to assess the reducing capacity. A solution composed of sodium acetate (300 mmol/L), Ferric Chloride (20 mmole/L) and 2, 4, 6-tripyridyl-s-triazine (TPTZ) solution (10 mmole/L) was mixed with fresh garlic extract. This mixture underwent incubation at 37C for 10 minutes. Ascorbic acid at different concentration ranging from 0µg/mL to 100µg/mL was used for calibration, with absorbance measurement at 593nm. The results were expressed as 01 mg of ascorbic acid equivalent to each gram of garlic extract.

Total Phenolic Contents (TPC) Assay: TPC assay following a modified protocol from Pie et al. 2020, good volume 25 Microsoft samples and falling statements were mixed and diluted in a 96 well plates. Subsequently 10% sodium carbonate 25 mL were added and the solution was incubated at 25C for 60 minutes absorbance was measured at 765 nm and the results were represented as per mg of Gallic acid equal.

Histology: Kidney's word dissected from the mice after above cited duration dosage. These organs were preserved in 10% formalin, dehydrated in graded alcohol solutions, cleared with xylene, and embedding in paraffin wax. Thin section (05 micrometer) obtained using rotatory microtome, followed by staining with hematoxylin and Eosin. Microphotographs were captured using M4000-D swift Japan binocular microscope with an "Ease-i-Image universal" camera.

Statistical analysis: First, mean values and standards deviations for body weight, kidney weight, and biochemical factors were calculated of each group to determine the average measurements and variability. Then an ANOVA (one-way) was performed to identify the significant differences between control and treated groups. If ANOVA indicated the differences, The Tukey's post-doc test was used to specify which group or groups differed from each other. All analysis were conducted using SPSS (standard package for social sciences) version 20 to ensure accurate and efficient data processing. The level of significance was $p < 0.05$, which showed result, are statistically significant.

RESULTS

The contemporary research's outcomes were presented in tables and figures. The administrative dose and antidote showed significantly influence the animal's overall physique particularly kidney.

Body weight: The body weight of each group was expressed as mean + S.E.M. Those receiving BPA exhibit are notable reduction in body weight over the 28 days. The concentration of BPA in G-III group showed prominent degree of weight reductions.

Conversely the group subsequently exposed to the G-IV antidote (fresh garlic extract +BPA) showed sufficiently recovery in body weight in the last week (4th week). The groups G-I., G-II and G-V demonstrated no significant change in their body weight (Figure 1).

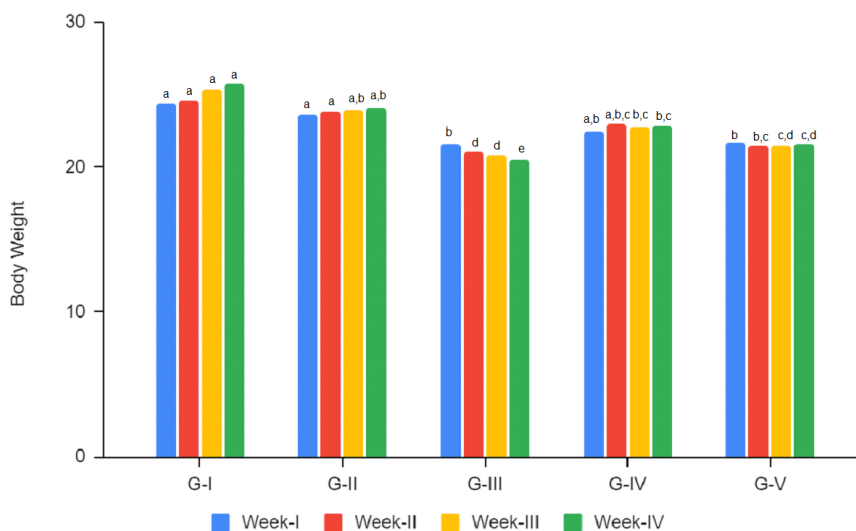


Figure (1): Graph showed the variation in body weight during of control and treated groups through the experiments. Alphabets shows the level of significance ($P \leq 0.05$).

Kidney weights: After 28 days of dosage, the G-III group displays reduction in kidney weight as in body weight. This decrease was observed to be gradual with increasing concentration of BPA. In contrast, the control group and, vehicle group and garlic extract group exhibit similar kidney weights indicating of no effect (Table 1).

Kidney width: Following kidney weight and length measurements, BPA exposure recorded the reduction in kidney widths. The BPA-exposed group exhibited reduction in kidney width compared to the G-I., G-II and G-V groups. This trend of decreasing width intensified with dosage duration (Table 1).

Kidney length: The trend in kidney length among the BPA exposed group mirrored the results of kidney weight. Data collected post-experimentations unequivocally demonstrated that the G-III gradual reduction in kidney length compared to the groups G-I., G-II and G-V. Furthermore, an increase in BPA concentrations on correlated with the gradual decrease in body length (Table 1).

Reno-Somatic index: The Reno somatic index or nephrons somatic index indicates the percentage of variation animal's physique by comparing kidney weight to the final body weight. Among the group receiving BPA (G-III) doses, RSI values showed minimal deviation compared to the control group. However, the fresh garlic extract treated group displayed a slightly higher value relatively to the other groups (Table 1).

Table (1): This table showed the trend in the variation of kidney weight, length width and Reno-somatic index in control and treated groups. Alphabets shows the level of significance ($P \leq 0.05$).

| Parameters | G-I | G-II | G-III | G-IV | G-V |
|--------------------|--------------|--------------|--------------|--------------|--------------|
| Kidney weight | 152.13±1.22 | 149.98±0.758 | 134.34±1.459 | 152.33±0.626 | 152.14±0.577 |
| Kidney length | 4.72±0.003 | 4.70±0.003 | 4.11±0.001 | 4.66±0.001 | 4.77±0.001 |
| Kidney width | 4.34±0.021 | 4.36±0.001 | 3.99±0.001 | 4.22±0.001 | 4.28±0.001 |
| Reno-somatic index | 0.0059±0.001 | 0.0062±0.003 | 0.0065±0.023 | 0.0067±0.050 | 0.0071±0.050 |

Feed Consumption: During the experiment, the intake of feed by the experimental animals observed and found variation in the both treated and control groups. Unlike the other groups BPA, treated (G-III) showed a strange trend in feed consumptions. There was a shear increased in the feed consumption in the

second week of experiment but it dropped as the experiment proceeded. Ultimately, there was significant decrease observed by the conclusion of the experiment. However, in fresh garlic extract (G-IV) treated group showed significant recovery in feed consumption (Figure 2).

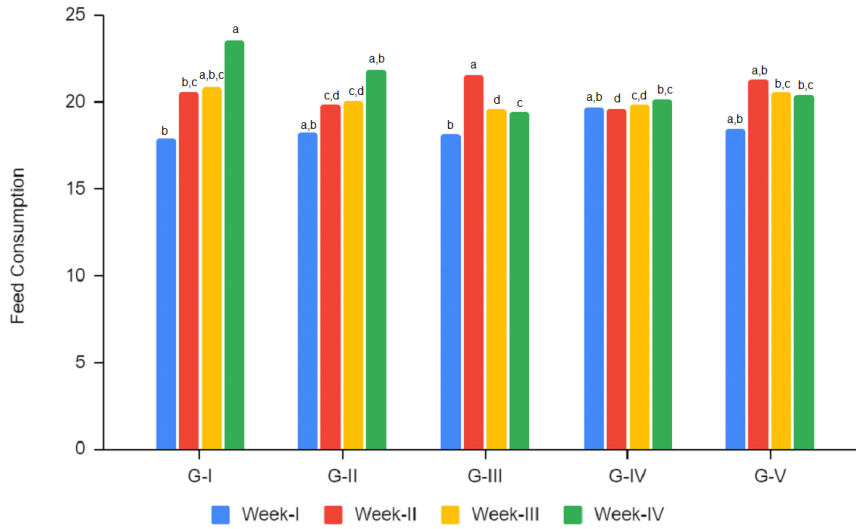


Figure (2): The Graph showed the feed consumption level in control and treated groups during the experiment. Alphabets shows the level of significance ($P \leq 0.05$).

Fecal waste production: The trend of fecal waste production by the experimental animals massively decreased in the BPA treated group (G-III) as compared to the control groups. This kind of

observation remained same and continuously decreased in the amount fecal production. However, the fresh garlic extract mitigates the effect and showed a normal fecal production (G-IV) (Figure 3).

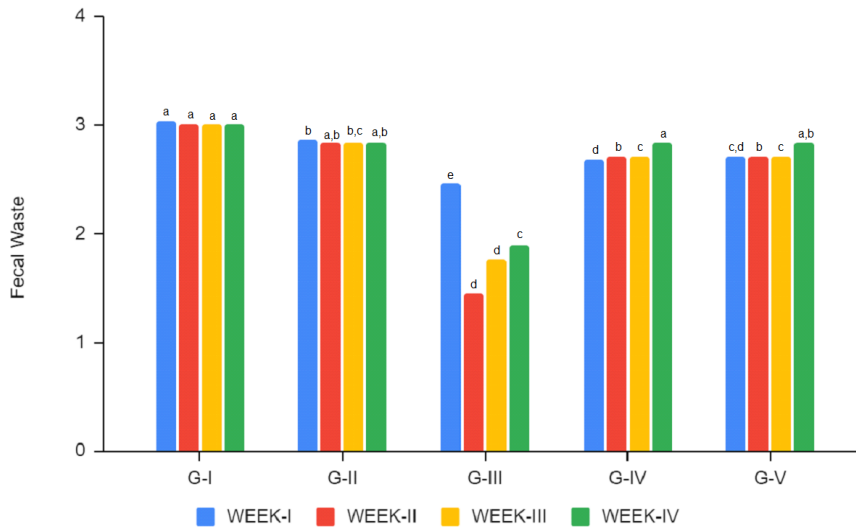


Figure (3): The graph showed the values of fecal waste production (each week/cage) in control and treated groups.

Renal Function Test: The renal function tests (RFT) conducted to assess kidney toxicity exposed to BPA. Statistical analysis via the one-way ANOVA ($P \leq 0.05$) of the data revealed that (G-III) group

exposed to BPA demonstrated elevated level of urea and creatinine. The results elucidated that garlic extract aided in mitigating abnormal urea and creatinine levels in the mice (G-IV) (Table 2, Figure 4).

Table (2): The table showed the values of urea and creatinine in the control and treated groups. Alphabets shows the level of significance ($P \leq 0.05$).

| Parameters | G-I | G-II | G-III | G-IV | G-V |
|------------|---------------------|---------------------|-------------------|---------------------|---------------------|
| Urea | 44.16c,d \pm 0.20 | 44.63c,d \pm 0.43 | 59.65a \pm 0.16 | 45.70c,d \pm 0.14 | 44.80c,d \pm 0.14 |
| Creatinine | 0.83b \pm 0.04 | 0.85b \pm 0.03 | 1.20a \pm 0.05 | 0.81b \pm 0.02 | 0.85b \pm 0.02 |

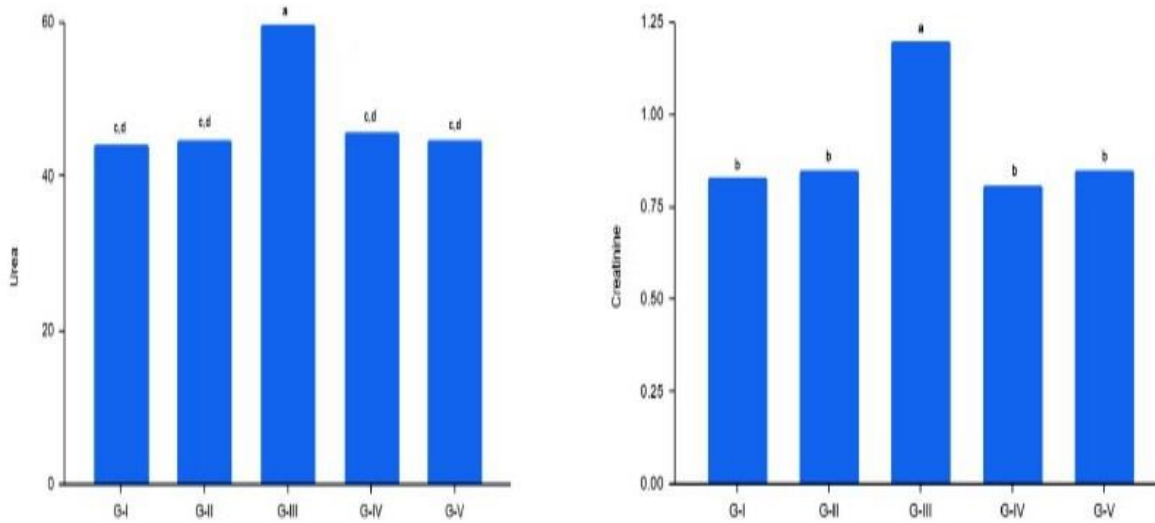


Figure (4): This graph showed the variation in Urea (Left) and Creatinine (Right) in control and treated groups.

Stress Enzymes: (FRAP & TPC): Simultaneously an evaluation of the therapeutic potential of garlic extract was conducted, including Total phenolic

contents (TPC) and Ferric Reducing Antioxidant Power (FRAP) assays, to observed and quantify its impact on rejuvenation of damage kidney cell (Figure 5).

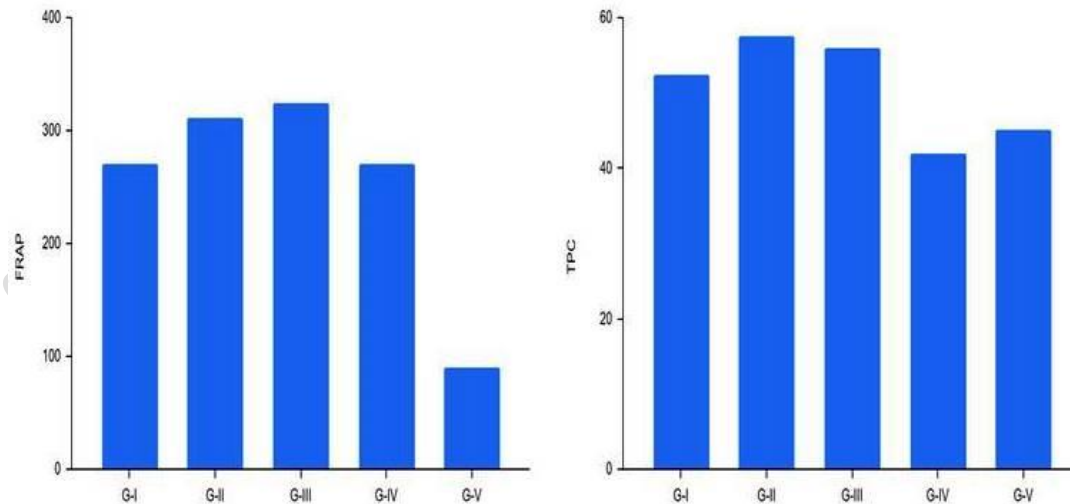


Figure (5): This graph showed the antioxidant assessment using FRAP (Left) and TPC (Right) techniques in control and treated groups.

Histology: Histological examination of kidney tissues provides further insight into the effectiveness of countering extract on countering the effect of BPA on kidney. The control and fresh garlic extracted groups exhibited normal tissue characterized by intact glomerular structures, well-preserved proximal tubules, organized epithelial cells, and compact renal cystic lumens. Cytoplasmic staining with hematoxylin

and eosin demonstrated excellent structure with nuclei retaining their original round shape. Conversely, BPA-exposed group displayed a significant renal structure damage including, including swollen tubules, shrunken and nearly disappearing capillaries, hyperplasia from glomerular destructions, and atrophy. The prominent symptoms sclerosis due to meningeal proliferations (Figure 5).

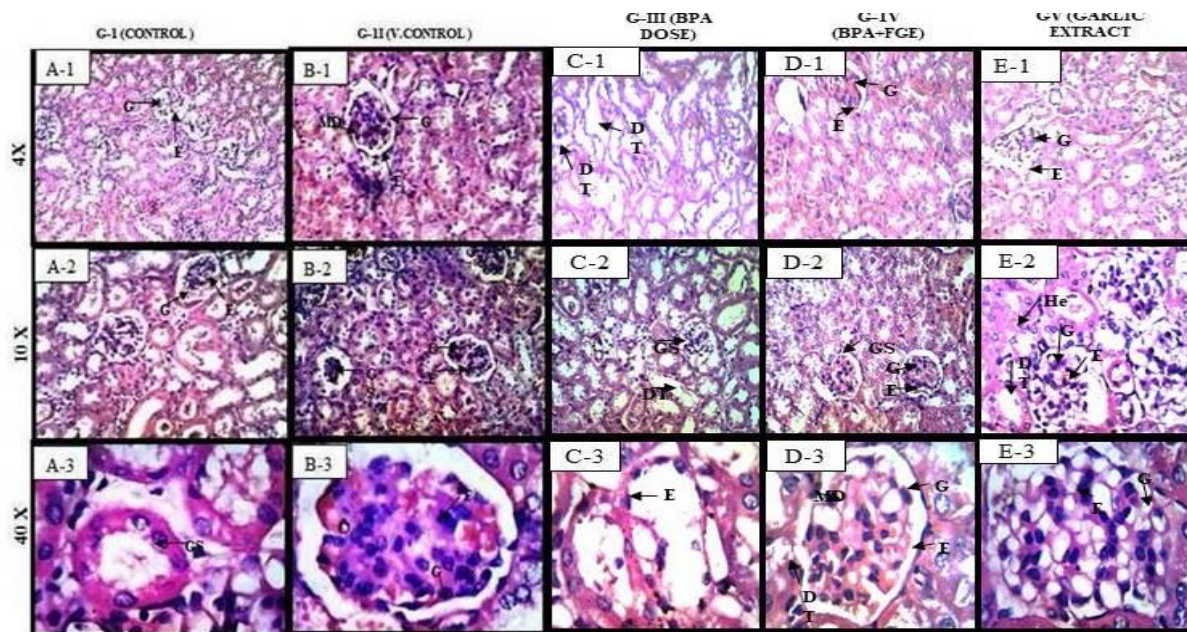


Figure 4: In the kidney transverse sections of mice, the control and vehicle control groups (G-I and G-II) exhibited histologically normal renal tissue, characterized by densely packed renal tubules embedded in a vascular interstitium. Conversely, the group treated with Bisphenol-A (BPA) (G-III) displayed notable histological alterations, including renal tubule necrosis, interstitial lymphoplasmacytic nephritis, and hyperemia. Ultrastructural changes in this group encompassed a reduction in the number and size of microvilli in the epithelial cells of the proximal convoluted tubules, deformation and shrinkage of nuclei, malformation of mitochondria, and cytoplasmic folding. Additionally, dilation of the urinary space in renal corpuscles and the formation of endothelial electron-dense deposits in glomerular basement membranes were evident. In contrast, the group treated with BPA in conjunction with fresh garlic extract (G-IV) demonstrated improved ultrastructural features, including enhanced numbers and sizes of microvilli in the epithelial cells of proximal convoluted tubules, a mixture of deformed and shrunken nuclei alongside healthy nuclei, reduced malformation of mitochondria and minimal or absent cytoplasmic folding. Furthermore, there was a decrease in the dilation activity of the urinary space in renal corpuscles and a reduced formation of endothelial electron-dense deposits in glomerular basement membrane. These intermediary conditions as depicted histological sections, underscore the ameliorative effects of the fresh garlic extract on kidney structure.

DISCUSSIONS

The significant increase in industrialization standards has been identified as a primary driver of environmental pollution. Various studies have acknowledged BPA as a hazardous pollutant with potential implications for human health. This escalating presence of BPA in the environment not only poses a threat to the human well-being but also exerts adverse effects on the ecosystems [28]. Numerous investigations have been undertaken to mitigate the deleterious impacts of such toxic chemicals through the utilization of biological agents like herbs [8]. The current study unveiled compelling evidence of the efficacy of fresh garlic extract in ameliorating BPA-induced toxicity. The presence of allicin and various other chemical agents ranked garlic as a perfect remedy against the toxicity of plasticizer, especially BPA [3].

BPA is recognized as a carcinogenic substance for humans and is associated with severe conditions, affecting the renal, cardiac, hepatic, and reproductive systems. Given its persistence in the body, prolonged exposure to this chemical can lead to critical outcomes, potentially fatal [1, 26]. Recent research has revealed that extended exposure to BPA contributes to a reduction in body weight [18, 31]. Individuals

susceptible to BPA experience heightened stress levels, characteristic of a boosted immune system. Furthermore, neural irregularities are observed in such instances, hampering the assimilation of nutrients. Consequently, individuals in such circumstances exhibit a diminished capacity for fat accumulation, resulting in weight reduction and other associated biometric analysis [12].

Moreover, all the vital organs affected by BPA toxicity, including liver, kidney, heart, and reproductive structures, are the prime targets. It not only damages their internal morphology but also disrupts their secondary functions [23, 21].

Garlic exhibits potent anti-toxic properties that facilitate optimal food intake by promoting normal gastric activity and regulating body weights [5]. Animals subjected to BPA exposure face an elevated risk of structural and functional impairment of the kidneys [20, 15]. Garlic extract effectively mitigates the detrimental effects of BPA in affected mice.

The results of this research indicate that BPA influences food intake, leading to a deviation in fecal waste production compared to normal conditions. This deviation may be attributed to the stress and distortion induced by BPA toxicity, causing

deregulation in gastrointestinal track. The potential underlying mechanisms of these effects were discussed. These findings were coincided with outcomes, reported by Zhu [33].

Recent studies have elucidated the pivotal role of BPA in affecting creatinine and urea levels, which is linked to the kidney's responsibility for their elimination. However, excessive renal activity compromises both its Physiology and functional capacity. The deteriorative impacts of BPA on renal health can be attenuate through the applications of fresh garlic extract. The current research findings were corroborated by the work of Jiang et al., 2020[13].

Histological examination of kidney tissue revealed distinct alteration, including nephron structural, deteriorations, glomerular dilation, epithelial contractions, and elevated urea and critical levels. Nunez et al., (2023) showed similar effects of BPA on kidney tissues when compared with this research work [24]. Another noteworthy point is that these changes further intensified with increased BPA concentrations and duration. These outcomes concurrent with the research Faheem et al., 2021; 2023[21, 23]. Recent studies unequivocally affirm that BPA constitutes a significant contributor to the renal injuries, irrespective of exposure levels. The findings of Yamasaki et al., 2001[32] further bolsters the assertions of this study.

CONCLUSIONS

BPA has been substantiated as a hazardous environmental pollutant primarily gained entry in organisms via oral path. Recent investigations have scrutinized the deleterious impact of BPA on both the structural and functional integrity of the kidneys. Current research provides compelling evidence supporting the antioxidant properties of garlic extract, suggesting its potential benefits for safeguarding kidney's health.

Significance: The significance of garlic against BPA for public health lies in its potential to mitigate its toxicity. Antioxidant and protective properties help to reduce the oxidative stress and damage. By incorporating the garlic extract simply in diet, it may possible to lower the risk of BPA-related health issues i.e., kidney damage and hormonal imbalance, thereby contributing to improved public health outcomes.

Suggestions: Further research is needed to confirm these results and explore the underlying the mechanism in detail. This will provide a deeper understanding of the effects and establish the broader applicability and implication of the findings.

Limitation of the study: Species specificity, Dose dependency, duration of exposure, lacking of precise mechanistic understanding, Interactions with other compounds were considered limitation of this study.

Ethical approval and consent to participate: Ethical approval for this study obtained from the local

Ethical Body of University of the Punjab, Lahore, Pakistan and prior consent acquired from all the participants for their inclusion in the study.

Consent for publication: All authors were agreeing for the publication at this journal.

Availability of data and material: Yes

Author's contribution:

Faheem Nawaz: Submission and Corresponding, Conceptualization, Experimental design, Execution of experiments, Data collection, Preparation of Manuscript, revision and editing. **Chaman Ara:** Co-supervised, helping hand in manuscript write up, editing and data analysis, Proof-reading and Finalization. **Asmat Ullah:** Supervised and interpretation of Data, Ethical Considerations. **Sana Akbar:** help in Rearing and caring of experimental animals, Photography of Histology slides. **Madeesha Mehboob:** help in Literature Review, Literature citation and Histology. **Naveed Akhtar:** help in Data collection, Statistical Analysis.

Competating Interest: No

Funding: N/A

Acknowledgment: I owe my sacred acknowledgments to all contributors.

REFERENCES

- 1] Akash MS, Rasheed S, Rehman K, Imran M, Assiri MA. Toxicological evaluation of bisphenol analogues: preventive measures and therapeutic interventions. *RSC advances*. 2023;13(31):21613-28.
- 2] Anees S, Manzoor I, Fatima K, Hamid R, Ganie SA. GC-MS analysis and potential therapeutic efficacy of extracts from *Allium humile* Kunth in lowering dyslipidemia in wistar rat models. *Journal of Ethnopharmacology*. 2024 Feb 10;320:117478.
- 3] Batool S, Shaheen M, Shameem S, Aziz R, Batool S, Iram F, Aslam I, Kanwal U. Effects of aqueous garlic (*Allium sativum*) extract against di-(2-ethylhexyl) phthalate induced cytotoxicity in peripheral blood and liver of adult female mice. *Pharmaceutical Sciences Asia*. 2023 Jul 1;50(3).
- 4] Bindhumol V, Chitra KC, Mathur PP. Bisphenol A induces reactive oxygen species generation in the liver of male rats. *Toxicology*. 2003 Jun 30;188(2-3):117-24.
- 5] Boulekbache-Makhlouf L, Slimani S, Madani K. Total phenolic content, antioxidant and antibacterial activities of fruits of *Eucalyptus globulus* cultivated in Algeria. *Industrial crops and products*. 2013 Jan 1;41:85-9.
- 6] Chitra K, Latchoumycandane C, Mathur P. Effect of nonylphenol on the antioxidant system in epididymal sperm of rats. *Archives of toxicology*. 2002 Sep;76:545-51.
- 7] Dillon SA, Burmi RS, Lowe GM, Billington D, Rahman K. Antioxidant properties of aged garlic extract: an in vitro study incorporating human low density lipoprotein. *Life Sciences*. 2003 Feb 21;72(14):1583-94.
- 8] Dorriviv M, Zareyan A, Hosseinzadeh H. Garlic (*Allium sativum*) as an antidote or a protective agent against natural or chemical

- toxicities: A comprehensive update review. *Phytotherapy Research*. 2020 Aug;34(8):1770-97.
- 9] Gong Y, Han XD. Nonylphenol-induced oxidative stress and cytotoxicity in testicular Sertoli cells. *Reproductive toxicology*. 2006 Nov 1;22(4):623-30.
 - 10] Griffiths G, Trueman L, Crowther T, Thomas B, Smith B. Onions—a global benefit to health. *Phytotherapy Research: An International Journal Devoted to Pharmacological and Toxicological Evaluation of Natural Product Derivatives*. 2002 Nov;16(7):603-15.
 - 11] Hoque E, Sujun KM, Haque MI, Mustary A, Miah MA, Hossain MM, Islam MK. Evaluation of bisphenol a induced effects on blood bio-chemical constituents and histo-structure of liver in Swiss albino mice and its 'one health' perspectives. *J Vet Med One Heal Res*. 2019;1:75-83.
 - 12] Inadera H. Neurological effects of bisphenol A and its analogues. *International journal of medical sciences*. 2015;12(12):926.
 - 13] Jiang G, Ramachandraiah K, Murtaza MA, Wang L, Li S, Ameer K. Synergistic effects of black ginseng and aged garlic extracts for the amelioration of nonalcoholic fatty liver disease (NAFLD) in mice. *Food Science & Nutrition*. 2021 Jun;9(6):3091-9. (11)
 - 14] Kabuto H, Amakawa M, Shishibori T. Exposure to bisphenol A during embryonic/fetal life and infancy increases oxidative injury and causes underdevelopment of the brain and testis in mice. *Life sciences*. 2004 Apr 30;74(24):2931-40.
 - 15] Korkmaz A, Ahabab MA, Kolankaya D, Barlas N. Influence of vitamin C on bisphenol A, nonylphenol and octylphenol induced oxidative damages in liver of male rats. *Food and Chemical Toxicology*. 2010 Oct 1;48(10):2865-71.
 - 16] Lang IA, Galloway TS, Scarlett A, Henley WE, Depledge M, Wallace RB, Melzer D. Association of urinary bisphenol A concentration with medical disorders and laboratory abnormalities in adults. *Jama*. 2008 Sep 17;300(11):1303-10.
 - 17] Leonavičienė L, Povilėnaitė D, Bradūnaitė R, Vaitkienė D, Venalis A. Treatment of experimental amyloidosis with antirheumatic drugs. *Acta medica Lituanica*. 2010 Jan 1;17(1-2):17-29.
 - 18] Ma Q, Deng P, Lin Ms, Yang L, Li L, Guo L, Zhang L, He M, Lu Y, Pi H, Zhang Y. Long-term bisphenol A exposure exacerbates diet-induced prediabetes via TLR4-dependent hypothalamic inflammation. *Journal of Hazardous Materials*. 2021 Jan 15;402:123926.
 - 19] Ma Y, Liu H, Wu J, Yuan L, Wang Y, Du X, Wang R, Marwa PW, Petlulu P, Chen X, Zhang H. The adverse health effects of bisphenol A and related toxicity mechanisms. *Environmental research*. 2019 Sep 1;176:108575.
 - 20] Moreno-Gómez-Toledano R, Arenas MI, Vélez-Vélez E, Coll E, Quiroga B, Bover J, Bosch RJ. Bisphenol A exposure and kidney diseases: systematic review, meta-analysis, and NHANES 03–16 study. *Biomolecules*. 2021 Jul 16;11(7):1046.
 - 21] Nawaz F, Ullah A, Ara C, Mehboob M, Idran M. The Assessment of Histopathological Impacts of Bisphenol-A on the Liver in Mice. *RADS Journal of Biological Research & Applied Sciences*. 2021 Dec 14;12(2):90-7.
 - 22] Nawaz F, Ara C. Assessment of deleterious effects of bisphenol A (bpa) on steroidogenesis, sperm count, and spermatogenesis in a mammalian model. *JAPS: Journal of Animal & Plant Sciences*. 2021 Dec 1;31(6).
 - 23] Nawaz F, Ullah A, Ara C, Zaifat S, Idran M, Mehboob M, Azmet S. Assessing Bisphenol A (BPA) Induced Kidney Toxicity in Mammalian Model: A Comparative Study of Biometric, Histochemical, Histological and Behavioral Analyses. *RADS Journal of Biological Research & Applied Sciences*. 2023 Oct 10;14(1):1-0.
 - 24] Nuñez P, Arguelles J, Perillan C. Effects of short-term exposure to low doses of bisphenol A on cellular senescence in the adult rat kidney. *Histochemistry and Cell Biology*. 2023 May;159(5):453-60.
 - 25] Van Hemel SB, Pew RW, editors. *Technology for adaptive aging*. National Academies Press; 2004 Apr 25.
 - 26] Richter CA, Birnbaum LS, Farabolini F, Newbold RR, Rubin BS, Talsness CE, Vandenberg JG, Walser-Kuntz DR, Vom Saal FS. In vivo effects of bisphenol A in laboratory rodent studies. *Reproductive toxicology*. 2007 Aug 1;24(2):199-224.
 - 27] Sagar NA, Pareek S, Benkeblia N, Xiao J. Onion (*Allium cepa* L.) bioactives: Chemistry, pharmacotherapeutic functions, and industrial applications. *Food Frontiers*. 2022 Sep;3(3):380-412.
 - 28] Shipton L, Dauvergne P. Health concerns of plastics: energizing the global diffusion of anti-plastic norms. *Journal of Environmental Planning and Management*. 2022 Jul 7;65(11):2124-44.
 - 29] Su LJ, Zhang JH, Gomez H, Murugan R, Hong X, Xu D, Jiang F, Peng ZY. Reactive oxygen species-induced lipid peroxidation in apoptosis, autophagy, and ferroptosis. *Oxidative medicine and cellular longevity*. 2019 Oct 13; 2019(1):5080843.
 - 30] Suárez S, Sueiro RA, Garrido J. Genotoxicity of the coating lacquer on food cans, bisphenol A diglycidyl ether (BADGE), its hydrolysis products and a chlorohydrin of BADGE. *Mutation Research/Genetic Toxicology and Environmental Mutagenesis*. 2000 Oct 31;470(2):221-8.
 - 31] Vom Saal FS, Hughes C. An extensive new literature concerning low-dose effects of bisphenol A shows the need for a new risk assessment. *Environmental health perspectives*. 2005 Aug;113(8):926-33.
 - 32] Yamasaki H, Nagake Y, Makino H. Determination of bisphenol A in effluents of hemodialyzers. *Nephron*. 2001 Jul 1;88(4):376-8.
 - 33] Zhu M, Zeng R, Wu D, Li Y, Chen T, Wang A. Research progress of the effects of bisphenol analogues on the intestine and its underlying mechanisms: A review. *Environmental Research*. 2023 Dec 9:117891.
 - 34] Zugaro S, Benedetti E, Caioni G. Garlic (*Allium sativum* L.) as an Ally in the Treatment of Inflammatory Bowel Diseases. *Current Issues in Molecular Biology*. 2023 Jan 11;45(1):685-98