

Sudden infant death of monozygotic twin on the same day: a case report

Rayyan Al Ali^{1*}, Hamzeh Al Zabadi^{2,3*}, Noor Irshaid⁴

¹Forensic Medicine Institute, Faculty of Medicine and Health Sciences, An-Najah National University, Nablus, Palestine. ²Public health Department, Faculty of Medicine and Health Sciences, An-Najah National University, Nablus, Palestine. ³ Joint MD Program, Palestine Polytechnic University, Hebron, Palestine. ⁴Medicine Department, Faculty of Medicine and Health Sciences, An-Najah National University, Nablus, Palestine

*Corresponding authors: rayyanalali@najah.edu

Received: (29/10/2019), Accepted: (19/2/2020)

Abstract

Sudden Infant Death Syndrome (SIDS) represents a major leading cause of death among all racial and ethnic groups of infants between one month and one year of age. The exact cause of sudden unexpected death is still unclear, but there are multiple possibilities which presumed to explain it, such as: cardiovascular abnormalities, suffocation and infectious diseases. The occurrence of such death is extremely rare particularly in twins. For the first time in Palestine, we report a case of eight-week-old female twin who were found dead while sleeping on their right side. Their death occurred within 24 hours from each other. Extensive investigations were performed; no identifiable cause of death was discovered. This report demonstrates that low socioeconomic status of the family and unhealthy sleeping environment strongly influenced the sudden death of those monozygotic twin.

Keywords: Low socioeconomic status; monozygotic twins; Palestine; sudden infant death syndrome.

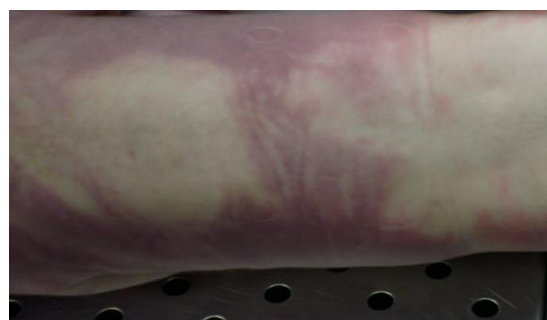INTRODUCTION

Sudden unexpected infant death (SUID), is a term used to describe any sudden and unexpected death, whether explained or unexplained (including sudden infant death syndrome [SIDS] and ill-defined deaths), occurring during infancy [1]. After case investigation, SUID can be attributed to suffocation, asphyxia, entrapment, infection, ingestions, metabolic diseases, arrhythmia-associated cardiac channelopathies, and trauma (unintentional or nonaccidental) [1]. SIDS is a subcategory of SUID and the term is used in cases of infant deaths that cannot be explained after a thorough investigation, including a scene investigation, autopsy, and review of the clinical history [1]. If the infants are twin and died within one day, the simultaneous definition is used [2]. Environmental factors and heart abnormalities can be some of the contributing factors for certain SIDS cases, for example familial long QT syndrome (LQTS) [3]. Sudden infant death syndrome and unexpected infant deaths are still a public health issue and constitute a major element in the field of forensic medicine investigations [4]. Here, we report a

case of sudden death of twin female infants on the same day.

Case presentation

Autopsies and examination were performed within 24 hours of the twin death by RA. The external examination showed two well developed, well-nourished female twins without any apparent dysmorphic features. Both had purple skin discoloration over their backs (Figure. 1) and postmortem rigidity had fully developed.



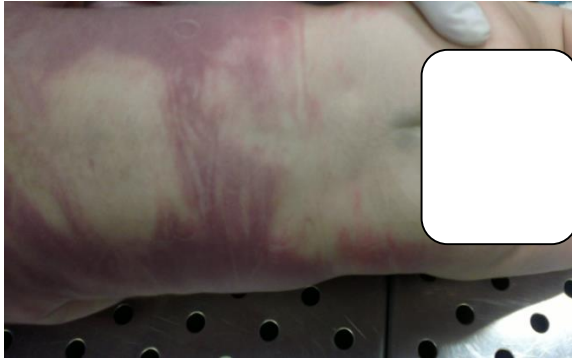


Figure (1): Postmortem purple discoloration of the twins back called livor mortis.

Twin A weighed 4330 g, her crown-to-heel length was 56 cm and the head circumference was 37 cm. Twin B weighed 3880 g, her crown-to-heel length was 58 cm and the head circumference was 37 cm. Each female baby was covered with a thick orange-colored wool blanket, wear a diaper, double undershirts and wool-made trousers. There was no evidence of trauma. No injuries were noted around nostrils, mouth, ano-genital area or on the neck. No scleral or conjunctival petechial hemorrhages were noticed. The anterior fontanels in both were open and normal in shape. The skull bones showed no fractures. The meninges appeared normal. The brain weighed 470 g in twin A and 460 g in twin B. On external examination, there were multiple purple skin discolorations on the babies' backs but their sizes were smaller than 2 mm. Upon internal examination, the hearts of both looked normal without any congenital abnormalities. However, there were numerous petechial hemorrhages on the epicardial surfaces of their hearts called Tardieu spots (Figure. 2; Twin A: 20 g; twin B: 25 g), as well as multiple ecchymosis scattered all over their thymuses.

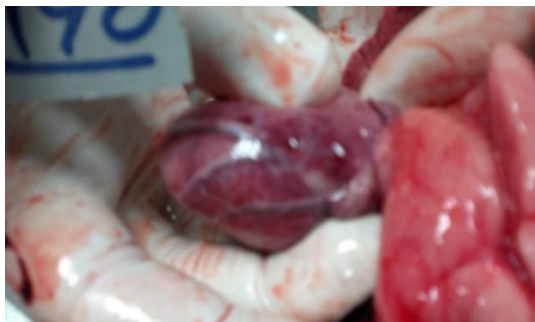

Figure (2): Petechial hemorrhages on the epicardial surfaces of the hearts.

The lungs (twin A: left 40 g and right 55 g; twin B: left 50 g and right 55 g) were markedly edematous with multiple petechial hemorrhages all over the pleura (Figure 3). There were no foreign bodies or any materials could obstruct the airways, they were totally patent.

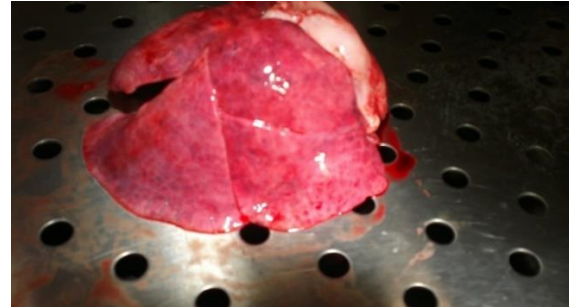

Figure (3): Edematous lungs with multiple petechial hemorrhages all over the pleura.

In the abdominal cavities, we did not find any abnormal collections of blood or pus. The stomachs for both contained whitish-colored gastric contents, with no suspicious odor of any toxic material. The internal abdominal organs appeared normal (twin A: liver 170 g, spleen 15 g, left kidney 15 g, right kidney 10 g; twin B: liver 150 g, spleen 25 g, left kidney 25 g and right kidney 25 g).

The histopathological examinations for most of the internal organs did not show any leading cause of death. In twin A: the microscopic appearance of the lungs showed focal edema and slight acute inflammatory changes while in twin B, there was also focal edema with mild chronic bronchitis.

Systemic toxicological analysis was performed using routine methods on blood samples to assess any narcotic, sedative or chemical materials that could contribute to their deaths. We did not find any of these in their samples. We did not conduct any genetic tests due to unavailability of these tests in our laboratories.

DISCUSSION AND CONCLUSIONS

The investigation of death of these twins was thorough, including a complete autopsy, an examination of the death scene and a review of the babies' clinical history. No evidence of bruising or previous trauma was found. There were no stains, vomit, or any apparent signs of abuse or neglect. Their

clothes were suitable for the weather. The babies appeared well-nourished and well cared for. Their nutritional status was good. They were breastfed dependent with extra artificial milk formula, adhered to the recommended vaccination program in Palestine. They had already received the first dose of Diphtheria, Pertussis and Tetanus vaccine (DPT), Hemophilus influenzae type B vaccine (Hib) and oral polio vaccines (OPV). We did not know the exact interval between the last OPV dose and the date of death. However, according to the parents' story it might be given 2 to 3 days before their death, as the 1st dose of OPV vaccine is usually given at the age of two months according to the Palestinian vaccination program.

According to the mother, she changed the diapers, fed the babies and let them sleep around 10:00 am, on their right side in a small crib where there is an enough space for each of them as usual. One hour later, the mother found them unresponsive, but their bodies were still warm. The police were informed; scene investigation was done. They live in a small well ventilated house located in a crowded neighborhood of the Old City of Nablus. An electric heater is usually used to warm the room but it was turned off few hours before the event. The babies usually sleep in the same room with their parents, but in a separate crib. It is worth mentioning that bed sharing with an older sibling is associated with an increased risk of SIDS [5]. However, there is no enough data of the increasing risk of SIDS in co-bedding with a twin [6]. Environmental tobacco smoke has been found to be associated with SIDS [2]. In our case, carbon monoxide may affects their death as the father smokes inside the home during the mother's pregnancy and after delivery of the twins [7, 8]. Their father is a heavy smoker, but their mother is not which is more important as the maternal smoking is the second most important modifiable risk factor for SIDS [4].

There was no apparent complications or medical conditions through the pregnancy. The mother committed to a regular visit program to her obstetrician. She delivered the twin by cesarean section after 34 weeks of gestation which might increase their chance of SIDS as the lower the gestational age the

higher the risk of SIDS [9, 10]. They were admitted to the neonatal intensive care unit (NICU) for three days due to their prematurity and low birth weight.

There was no family history of a similar event. They had a daughter with cardiac abnormalities who underwent a cardiac surgery, but unfortunately died at 11th month of age. Although, congenital cardiac abnormalities have been hypothesized to play a role in some SIDS cases, particularly primary genetic arrhythmogenic disorders such as familial long QT syndrome (LQTS), we were unable to do any genetic tests. However, both post-mortem and clinical studies of SIDS cases have provided a supporting evidence of the cardiac genetic disorders in SIDS [3].

The parents also have a history of still birth twin at 24 weeks of gestation. Although sudden infant death syndrome could not be confirmed, some common characteristics of SIDS exist there, such as the age at death, socio-economic disparities, previous pregnancy of twins and sudden death while sleeping. All these characteristics were found in our case.

SIDS is described as a sudden and silent medical disorder that can happen to any seemingly healthy infant. It is a very uncommon and unexpected event. We do not know the exact annual cases of SIDS because a full history, careful examination of the death scene, autopsy, genetic testing and toxicological analysis – which are all needed to diagnose SIDS - are not always performed.

In our case we report a sudden infant death involving 8-week aged female twin on the same day. Despite thorough investigations, nothing was able to explain what happened. The low socioeconomic status of the family, and unhealthy sleep environment that were apparent in our case, may strongly support the final diagnosis of SIDS.

ACKNOWLEDGEMENTS

The twins' parents are acknowledged for giving their consent to publish this report. An-

Najah National University is acknowledged for providing support.

Competing interests

The authors declare that they have no competing interests.

Consent for publication

Written informed consent for publication of infants' clinical details and/or clinical images was obtained from the parent of the babies. A copy of the consent form is available for review by the Editor of this journal from Dr. Rayyan Al Ali (Head of Forensic Medicine Institute at An-Najah National University). This case report was approved by the Institutional Review Board (IRB) ethical committee at An-Najah National University.

REFERENCES

- 1) Moon R, Darnall R, Feldman-Winter L, Goodstein M, FR. H. SIDS and Other Sleep-Related Infant Deaths: Updated 2016 Recommendations for a Safe Infant Sleeping Environment. *Pediatrics*. 2016; 138(5): e20162938.
- 2) Balci Y, Tok M, Kocaturk BK, Yenilmez C, Yirulmaz C. Simultaneous sudden infant death syndrome. *J Forensic Leg Med*. 2007; 14(2): 87-91.
- 3) Sweeting J, Semsarian C. Cardiac abnormalities and sudden infant death syndrome. *Paediatr Respir Rev*. 2014; 15(4): 301-306.
- 4) Huang P, Yu R, Li S, Qin Z, Liu N, Zhang J, et al. Sudden twin infant death on the same day: a case report and review of the literature. *Forensic Sci Med Pathol*. 2013; 9(2): 225-230.
- 5) Hauck FR, Herman SM, Donovan M, Iyasu S, Merrick Moore C, Donoghue E, et al. Sleep environment and the risk of sudden infant death syndrome in an urban population: the Chicago Infant Mortality Study. *Pediatrics*. 2003; 111(5 Pt 2): 1207-1214.
- 6) Tomashek KM, Wallman C, Committee on F, Newborn American Academy of Pediatrics. Cobedding twins and higher-order multiples in a hospital setting. *Pediatrics*. 2007; 120(6): 1359-1366.
- 7) Kum-Nji P, Mangrem CL, Wells PJ. Reducing the incidence of sudden infant death syndrome in the Delta region of Mississippi: a three-pronged approach. *South Med J*. 2001; 94(7): 704-710.
- 8) Ramos V, Hernandez AF, Villanueva E. Simultaneous death of twins. An environmental hazard or SIDS? *Am J Forensic Med Pathol*. 1997; 18(1): 75-78.
- 9) Malloy MH, Hoffman HJ. Prematurity, sudden infant death syndrome, and age of death. *Pediatrics*. 1995; 96(3 Pt 1): 464-471.
- 10) Sowter B, Doyle LW, Morley CJ, Altmann A, Halliday J. Is sudden infant death syndrome still more common in very low birthweight infants in the 1990s? *Med J Aust*. 1999; 171(8): 411-413.